

Coexistence of Type B Insulin Resistance and Chronic Inflammatory Demyelinating Polyneuropathy (CIDP) in Type 2 Diabetes Mellitus: Various Manifestations With the Same Pathophysiologic Base?

Clinical Medicine Insights: Case Reports
Volume 15: 1–4
© The Author(s) 2022
Article reuse guidelines:
sagepub.com/journals-permissions
DOI: 10.1177/11795476221144186



Maryam Heidarpour¹, Amir Aria², Niloofar Javadi³, Mansour Siavash⁴, Mehrbod Vakhshoori⁵ and Davood Shafie⁶

¹Isfahan Endocrine and Metabolism Research Center, Isfahan University of Medical Sciences, Isfahan, Iran. ²Department of Internal Medicine, Alzahra Hospital, Isfahan University of Medical Sciences, Isfahan, Iran. ³Student Research Committee, School of Medicine, Isfahan University of Medical Sciences, Isfahan, Iran. ⁴Isfahan Endocrine and Metabolism Research Center, Isfahan University of Medical Sciences, Isfahan, Iran. ⁵Heart Failure Research Center, Cardiovascular Research Institute, Isfahan University of Medical Sciences, Isfahan, Iran. ⁶Heart Failure Research Center, Cardiovascular Research Institute, Isfahan University of Medical Sciences, Isfahan, Iran.

ABSTRACT: Chronic inflammatory demyelinating polyneuropathy (CIDP) is a rarely reported disease. The association between diabetes mellitus (DM) and CIDP has been a matter of controversy. Here we presented a 59-year old male patient with uncontrolled type 2 DM presented with simultaneous type B insulin resistance (TBIRS) and CIDP. Both blood glucose and neurological manifestations responded well to corticosteroid therapies. Although the pathogenesis of CIDP remains to be elucidated, the role of antibodies in the pathogenesis of TBIRS and CIDP might be a promising platform for further studies to provide additional insights into the origin of these 2 rare complications.

KEYWORDS: Diabetes mellitus, polyneuropathy, chronic inflammatory demyelinating polyneuropathy, case report

RECEIVED: April 17, 2022. **ACCEPTED:** November 21, 2022.

TYPE: Case Report

FUNDING: The author(s) received no financial support for the research, authorship, and/or publication of this article.

DECLARATION OF CONFLICTING INTERESTS: The author(s) declared no potential conflicts of interest with respect to the research, authorship, and/or publication of this article.

CORRESPONDING AUTHOR: Mansour Siavash, Isfahan Endocrine and Metabolism Research Center, Isfahan University of Medical Sciences, Hezar Jarib Avenue, Isfahan 81746-7346, Iran. Email: siavash@med.mui.ac.ir

Background

Chronic inflammatory demyelinating polyneuropathy (CIDP) was reported as the most common chronic immune-mediated demyelinating neuropathy, but still a rare disease. The reported prevalence ranges varied from 0.8 to 8.9 per 100 000 people. Reported data imply that diabetes mellitus (DM) might be considered a risk factor for the development of CIDP. Several mechanisms such as pre-existing nerve damage due to diabetic neuropathy, increased activation of pro-inflammatory cytokines, and disruption of the blood-nerve barriers due to microangiopathy promote the onset of CIDP in diabetic patients. First-line treatment options include corticosteroids and intravenous immunoglobulin (IVIg). Plasma exchange can also be administered when these treatments are ineffective, and immunosuppression can be considered in refractory disease.^{1,2}

Type B insulin resistance syndrome (TBIRS) is a rare autoimmune disorder with acquired polyclonal autoantibodies against the insulin receptor, subsequently leading to severe and refractory hyperglycemia. TBIRS is usually associated with autoimmune diseases, most commonly systemic lupus erythematosus (SLE). As TBIRS is a rarely reported disease, the treatment has traditionally been empirical, and several case reports of therapeutic efforts with cyclophosphamide, glucocorticoids, azathioprine, rituximab, and plasmapheresis have been published.³⁻⁷

This report presents a 59-year old patient who suffered from uncontrolled type 2 DM who presented with simultaneous TBIRS and CIDP ultimately responded well to corticosteroid therapy, resulting in markedly improved blood glucose levels and neurological manifestations.

Case Presentation

A 59-year old Iranian man was referred to the emergency department complaining of pain in lower limbs, tingling, weakness, impaired bilateral lower limb movement, foot drop, and frequent urination. He was diagnosed with type 2 DM 18 years before admission due to episodes of polydipsia and polyuria. However, initial treatment with the prescription of glibenclamide (10 mg/day), metformin (2000 mg/day), and dietary changes were unsuccessful, and fasting blood glucose concentration was maintained within the approximate range of 8.5 to 11 mmol/L (153–198 mg/dL).

Two years prior to admission, oral antidiabetic medication was suspended, and treatment with Neutral Protamine Hagedorn (NPH) insulin was initiated at doses of 30 IU in the morning and 20 IU at night, as well as 10 IU of regular insulin before meals. The patient had poor treatment compliance, and insulin doses were progressively increased to 240 IU (total daily dose), as well as the resumption of metformin (2000 mg/day) and liraglutide 2.4 (mg/day). His self-monitoring blood



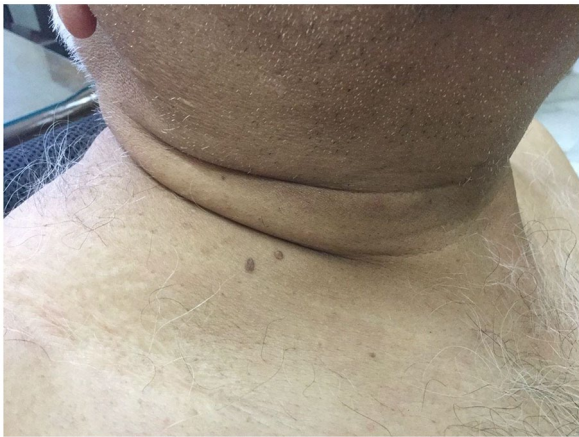

Figure 1. Patient's acanthosis nigricans and skin tags.

glucose ranges were 300 to 450 mg/dL. The patient was admitted with persistent symptoms, and random glucose measurement was 16.6 mmol/L (300 mg/dL).

Besides the past medical history of type 2 DM, he suffered from diabetic polyneuropathy and ischemic heart disease. His drug history was human insulin 240 IU (total daily dose), liraglutide (2.4 mg/day), metformin (2000 mg/day), aspirin (80 mg/day), valsartan (80 mg/day), bisoprolol (2.5 mg/day), and hydrochlorothiazide (25 mg/day).

On physical examinations, the patient was alert, and his vital signs were stable. The cardiopulmonary examination was unremarkable, but acanthosis nigricans and skin tags were observed in his neck (Figure 1). His body mass index was 30 kg/m². Neurological examinations showed no deep tendon reflex in lower limbs, disturbed sense of position, paresthesia in socks and gloves distribution, and reduced force in lower limbs (4/5) compared to upper limbs (5/5). His Gowers' sign was also found to be positive.

The patient's insulin dose was increased to 530 IU (total daily dose) during his admission, but he had uncontrolled blood glucose levels (HbA1c of 16.1% and fasting blood sugar (FBS) ranges of 400 to 500 mg/dL). Due to a daily insulin requirement of more than 2 IU/kg, the patient was diagnosed with severe insulin resistance. Other potential causes of high blood sugar, including pharmacological, neoplastic, infectious, and autoimmune etiologies, were ruled out. Blood biochemistry profile showed normal kidney and liver function tests. As the aforementioned tests were negative, TBIRS was considered a potential diagnostic hypothesis, and radioimmunoassay (Synlab, Barcelona, Spain) showed autoantibodies against the insulin receptor with a value of 5.23 U/mL (normal range: less than 1 U/mL).

On the other hand, because of the pain, tingling, and weakness of the lower limbs, the patient underwent Electromyography (EMG) and nerve conduction velocity (NCV) test, which revealed chronic axonal sensory-motor polyneuropathy suggestive of CIDP. Neurology consultation was requested, and 12 sessions of plasmapheresis were initiated (1500 L in every session). During initial sessions of plasmapheresis, his pain,

weakness, movement disorders of the lower extremities, and blood glucose levels improved significantly; However, due to the patient's refusal to continue plasmapheresis, oral prednisolone (60 mg/day) was initiated during hospitalization leading to amelioration of his neurological manifestations and significant blood glucose control. By the time of discharge, human insulin was discontinued, and he had controlled blood glucose with oral medications and homologous insulin (lispro). He was then discharged with prednisolone tablets (30 mg/day), homologous insulin (total dose of 100 IU/day), liraglutide (1.8 mg/day), acarbose (150 mg/day), metformin (1500 mg/day), glibenclamide (20 mg/day), and pioglitazone (30 mg/day).

In his follow-up 3 months after discharge, he reported significant improvements in his lower limb symptoms, but he still had mild pain in the proximal parts of his lower limbs. The daily dose of prednisolone was decreased to 15 mg/day. His FBS and HbA1c were also in acceptable ranges (120-150 mg/dL and 7.8%, respectively). Timeline of blood glucose, insulin dosages as well as HbA1c levels are illustrated in Figure 2.

Discussion

Studies have reported associations between CIDP and DM. However, there is still disagreement about whether CIDP is more closely linked to type 1 or type 2 DM.^{1,2} Based on the evidence, CIDP accounts for autoimmune diseases caused by increased autoantibodies. The initial diagnosis of CIDP remains clinical, supported by demonstrating demyelination on electrodiagnostic testing after standardized criteria such as those of the European Federation of Neurological Societies and the Peripheral Nerve Society (EFNS/PNS).⁸ The classical CIDP usually presents with a symmetrical, sensory, and motor polyradiculoneuropathy, areflexia, combined proximal and distal weakness, and often without severe pain. Distal motor deficits are more pronounced, and the sensory deficits are large-fiber-predominant. Systemic symptoms such as malaise, fever, dysautonomia, and severe pain are usually absent. However, cerebrospinal fluid, magnetic resonance imaging, and nerve pathology assessments are useful in some cases.⁸ Also, it has been suggested evaluation of novel antibodies against nodal proteins, skin and nerve biopsy, and corneal confocal microscopy might be useful for the early diagnosis of CIDP.²

The important point is that CIDP, unlike diabetic neuropathy, is treatable if diagnosed correctly. The primary first-line therapies are IVIg and corticosteroids. However, some studies reported that plasma exchange therapy was applicable.² The EFNS/PNS guideline recommends corticosteroids as well as IVIg as equally effective first-line treatments. Corticosteroids are associated with an increased risk for hyperglycemia. Therefore, in diabetic patients, IVIg may be a better therapy, but the risk of thromboembolic events should be carefully assessed. Plasma exchange is used less frequently owing to its impracticality and its short-term improvement duration, and repeated plasma exchange is often required.⁸

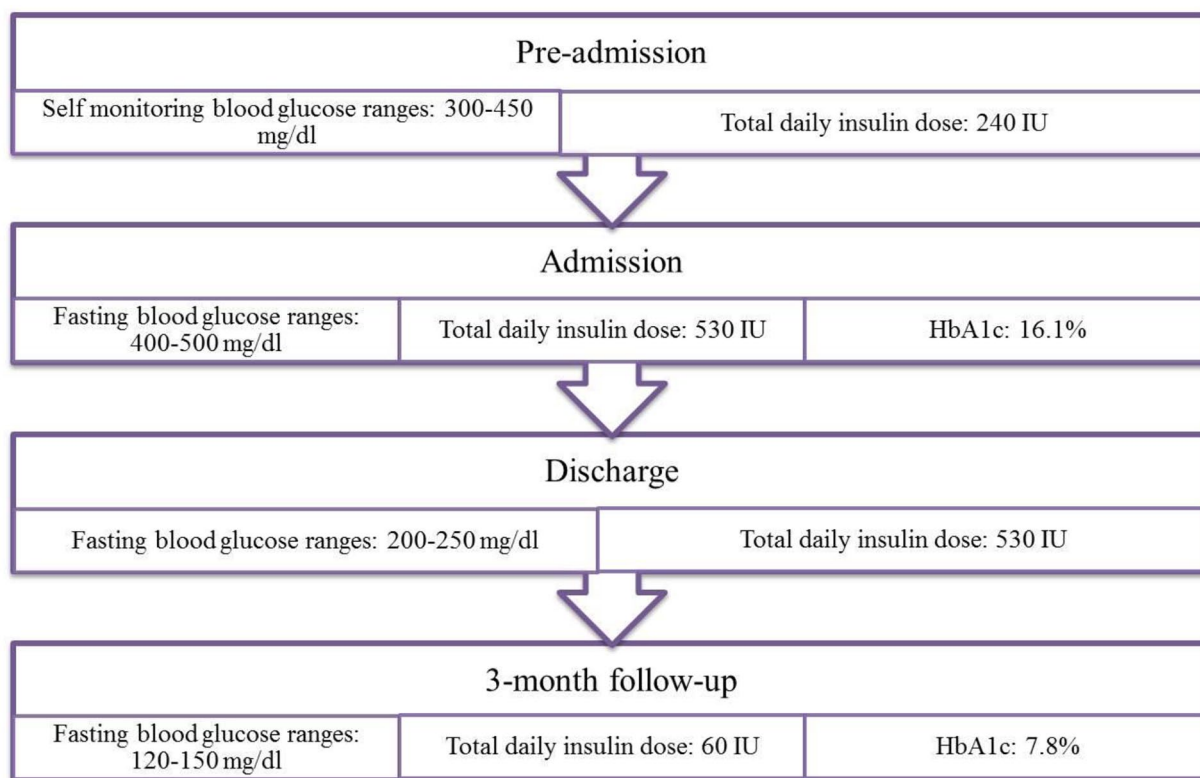


Figure 2. Timeline of blood glucose, insulin dosages and HbA1c from pre-admission to follow-up.

TBIRS is a rare autoimmune disorder with acquired polyclonal autoantibodies against the insulin receptor, which leads to severe and refractory hyperglycemia. TBIRS is usually associated with autoimmune diseases, most commonly SLE. It should be noted that most patients do not meet all the criteria for a specific autoimmune disease.⁶ Occasionally, patients develop initial or secondary hypoglycemia, in some cases with unsuppressed insulin, which could be due to defective degradation of insulin–insulin receptor complexes.⁹ Although the treatment is mainly done empirically, several case reports suggested therapeutic benefits of different agents, including cyclophosphamide, corticosteroids, azathioprine, rituximab, and plasmapheresis.³⁻⁷ However, combination immunosuppressive therapy is also reported in this regard. In a prospective cohort study, 22 patients with confirmed TBIRS were administered combination of rituximab, cyclophosphamide and high-dose pulsed steroids until remission (defined as hyperglycemia amelioration and insulin discontinuation and/or hyperandrogenemia normalization) followed by maintenance therapy with azathioprine. The patients were monitored for median of 72 months. The remission rate was reported as 86.4%. Although 3 patients experienced disease recurrence after remission, repeated immunosuppressive therapy resulted in complete response. In addition to no report of death during the study period, the authors stated combined immunosuppressive treatment can be implemented safely among TBIRS patients. However, worsening of hyperglycemia should be considered among these patients.¹⁰

In conclusion, despite the rarity of TBIRS with concurrent CIDP in the context of type 2 DM, the potential role of autoantibodies in their pathogenesis might be an interesting topic for future studies to assess the probable common origin of these 2 disorders.

Acknowledgements

None.

Author's Contribution

Study concept and design: M. H., D. S., M. S. Acquisition of data: M. H., A. A., N. J. Analysis and interpretation of data: Not applicable. Drafting of the manuscript: D. S., M. V., M. H., N. J., A. A. Critical revision of the manuscript for valuable intellectual content: M. V., D. S., M. H., M. S. Statistical analysis: Not applicable. Administrative, technical, and material support: M. H., D. S., M. S. Supervision: D. S., M. H., M. S.

Availability of Data and Materials

The datasets generated during and/or analyzed during the current study are not publicly available due to confidential issues but are available from the corresponding author on reasonable request.

Consent for Publication

Written informed consent was obtained from the patient for publication of this case report and any accompanying images. A copy of the written consent is available for review by the Editor-in-Chief of this journal

Ethical Approval and Consent to Participate

Ethical approval is not necessary for retrospective studies and case presentations in our institutional policies.

REFERENCES

1. Kuwabara S, Tsuneyama A, Misawa S. *Chronic Inflammatory Demyelinating Polyneuropathy and Diabetes*. BMJ Publishing Group Ltd; 2020:1035-1036.
2. Rajabally YA, Stettner M, Kieseier BC, Hartung H-P, Malik RA. CIDP and other inflammatory neuropathies in diabetes — diagnosis and management. *Nat Rev Neurol*. 2017;13:599-611.
3. Sjöholm Pereira MJ, Nilsson T, et al. Type B insulin resistance syndrome in a patient with type 1 diabetes. *Endocrinol Diab Metabol Case Rep*. 2020; 2020: 19-0157.
4. Willard DL, Stevenson M, Steenkamp D. Type B insulin resistance syndrome. *Curr Opin Endocrinol Diabetes Obes*. 2016;23:318-323.
5. Page KA, Dejardin S, Kahn CR, Kulkarni RN, Herold KC, Inzucchi SE. A patient with type B insulin resistance syndrome, responsive to immune therapy. *Nat Clin Pract Endocrinol Metab*. 2007;3:835-840.
6. Concepción-Zavaleta MJ, Ildefonso-Najarro SP, Plasencia-Dueñas EA, Quispe-Flores MA, Armas-Flórez CD, Luna-Victorio LE. Successful remission of type B insulin resistance syndrome without rituximab in an elderly male. *Endocrinol Diab Metabol Case Rep*. 2020;2020: 20-0110.
7. Kawashiri S-Y, Kawakami A, Fujikawa K, et al. Type B insulin resistance complicated with systemic lupus erythematosus. *Intern Med*. 2010;49:487-490.
8. Stino AM, Naddaf E, Dyck PJ, Dyck PJB. Chronic inflammatory demyelinating polyradiculoneuropathy-Diagnostic pitfalls and treatment approach. *Muscle Nerve*. 2021;63:157-169.
9. Bourron O, Caron-Debarle M, Hie M, et al. Type B insulin-resistance syndrome: a cause of reversible autoimmune hypoglycaemia. *Lancet*. 2014; 384:1548.
10. Klubo-Gwiedzinska J, Lange M, Cochran E, et al. Combined immunosuppressive therapy induces remission in patients with severe type B insulin resistance: a prospective cohort study. *Diabetes Care*. 2018;41:2353-2360.