
Case Report

THE FIRST FAMILY WITH KENNEDY DISEASE REPORTED FROM IRAN

Babak Zamani MD^{•*}, Masoud Hooshmand MD^{**}, **Mansoor Siavash**-Dastjerdi MD^{***},
Koorosh Shirkoool MD^{****}, Marzieh Nojoomi MD^{*****}, Mehdi Moghadasi MD^{*}

Kennedy disease is a rare X-linked, recessively-inherited disorder, which is diagnosed on the basis of clinical and electromyographic (EMG) findings, and more recently by polymerase chain reaction (PCR). The disease has been reported from around the world.

Here, we present 8 members of an Iranian family afflicted with the disease. The diagnosis was supported by PCR findings in 3 while in 5 cases the diagnosis was made based on clinical and EMG findings only.

The patients, all males, ranged in age from 20 to 85 years with the onset of gynecomastia during early adulthood and other more specific symptoms during the 5th and 6th decades of life with gradual onset and progression. The symptoms and signs included cramps, generalized weakness, dysphagia, dysphonia, tongue atrophy, tremor, generalized muscle atrophy, fasciculation, areflexia, and impotence. Four of them had hyperlipidemia and 3 had increased levels of blood glucose including one with frank diabetes mellitus. PCR, performed in 3 of the patients, showed an increase in cytosine-adenine-guanine (CAG) repeats on the long arm of X chromosome. Two heterozygote female carriers were diagnosed by the same test.

It is important to consider Kennedy disease in the differential diagnosis of lower motor neuron disorders considering its rather benign course and the need for genetic consultation for carriers.

Archives of Iranian Medicine, Volume 7, Number 3, 2004: 228 – 231.

Keywords: Bulbosplinal muscular atrophy • Kennedy disease • Kennedy syndrome

Introduction

Kennedy disease is a distinct, X-linked recessive disorder characterized by progressive wasting in the proximal muscles of the lower extremities and bulbar palsy. There is often a longstanding history of muscle cramps preceding the onset of weakness in the fifth decade of life. The presence of gynecomastia, postural tremor of upper limbs, perioral fasciculation, invariable involvement of tongue,

and sensory impairment in the lower limbs are the clues to diagnosis.^{1,2}

A mutation in the coding region of the androgen-receptor gene results in a variable increase in the number of cytosine-adenine-guanine (CAG) trinucleotide tandem repeats at this site. This can be detected by polymerase chain reaction (PCR) performed on DNA from peripheral leukocytes.^{3,4}

Kennedy et al first reported this disease in 1968. Since then, there have been a handful of reports from around the world. To the best of our knowledge, this is the first report of Kennedy disease from Iran.⁵⁻⁹

It is important to differentiate Kennedy disease from a more malignant, more frequent, and very similar disease, namely amyotrophic lateral sclerosis (ALS), because of the psychological implications of the diagnosis of the latter for the patient, his/her family, and the physician.

Authors affiliations: ^{*}Department of Neurology, Iran University of Medical Sciences, ^{**}Institute of Genetics, Tehran University of Medical Sciences, ^{***}Department of Internal Medicine, Iran University of Medical Sciences, ^{****}Department of Neurology, Toos General Hospital, ^{*****}Department of Community Medicine, Faculty of Medicine, Iran University of Medical Sciences, Tehran, Iran.

•Corresponding author and reprints: Babak Zamani, MD, No. 96, Mansoor St., Mottahari Ave., Tehran, Iran. Fax: +98-21-8701746, E-mail: zamani@iranneurology.com.

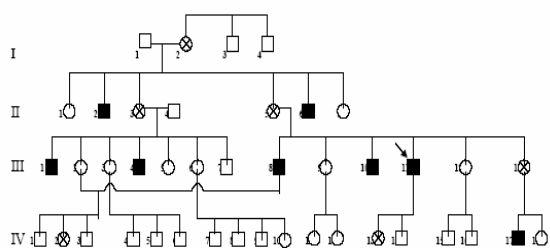


Figure 1. Four-generation pedigree of the index case.

□ healthy male ○ healthy female ⊗ carrier female
 ■ male with the disease ↘ the proband.

Case Report

A family (Figure 1) with 40 members in generations came to our notice when one member (the proband, case III-11) presented with the classic symptoms of the disease. He was a 58-year-old man with a history of gynecomastia for about 20 years and impotence for 8 years. He began to experience weakness, fasciculations, and cramps from the age of 43 years with a very slow progression rate. A few years later, he developed mild bulbar palsy and limb tremor. His neurologic examination showed prominent perioral and tongue fasciculations with atrophic changes. He had dysphonia, mild proximal weakness with atrophy, diffuse fasciculations and areflexia in all limbs, waddling gait, fine postural tremor in hands,

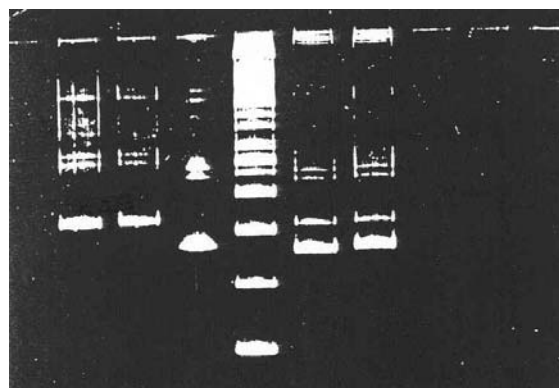


Figure 2. PCR in 2 carriers [IV-2 and IV-13 (right)], 2 patients [III-1 and III-8 (left)] normal person, and marker (middle).

and no sensory signs. The systemic examination was unremarkable except for the presence of gynecomastia. He had hyperglycemia, mild hyperlipidemia, and an increase in the serum level of creatine phosphokinase. His electromyographic exam showed prominent neurogenic changes in all the examined muscles including bulbar muscles (Figure 2). The nerve conduction studies were unremarkable except for slightly decreased sensory nerve action potential amplitudes. PCR was performed and an increased number of CAG repeats were observed as an abnormal band compared to a normal subject (Figure 3).

Seven other members of this family were diagnosed as Kennedy disease based on clinical and electromyographic examinations (in 2 of whom PCR supported the diagnosis). Findings are

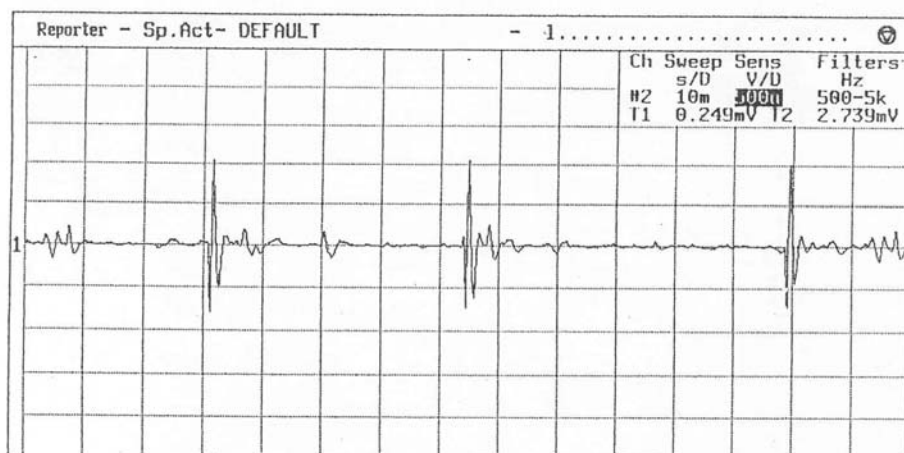


Figure 3. Electromyographic tracing from the index case showing prominent neurogenic changes. [Contraction (right deltoid muscle), sensitivity = 1 mv]

Table 1. Data from the 8 patients diagnosed as Kennedy disease.

Case	Age (yr)	Age of onset	Symptoms and signs	Laboratory findings
III-11 (proband)	58	4 th decade	<ul style="list-style-type: none"> • Gynecomastia, • cramps, • generalized weakness, • dysphagia, • dysphonia, • tongue atrophy, • tremor, • atrophy, • fasciculation, • areflexia, and • impotence 	<ul style="list-style-type: none"> • CPK ↑, • LDH ↔, • cholesterol ↑, • triglyceride ↑, • neurogenic changes on EMG, and • CAG repeats on Xq in PCR ↑
II-2	85	6 th decade *	<ul style="list-style-type: none"> • Gynecomastia, • atrophy, • dysphagia, • fasciculation, and • dysphonia 	<ul style="list-style-type: none"> • Cholesterol ↑, • triglyceride ↑, and • blood glucose ↑,
II-6	77	6 th decade *	<ul style="list-style-type: none"> • Gynecomastia, • atrophy, • dysphagia, • fasciculation, • dysphonia, and • tremor 	<ul style="list-style-type: none"> • Blood glucose ↑
III-1	61	6 th decade *	<ul style="list-style-type: none"> • Gynecomastia, • weakness, • atrophy, • dysphagia, • impotence, • tremor, • areflexia, and • prominent distal weakness 	<ul style="list-style-type: none"> • CPK ↑, • LDH ↔, • cholesterol ↑, • triglyceride ↑, • blood glucose ↔, and • CAG repeats on Xq in PCR ↑
III-4	46	—	<ul style="list-style-type: none"> • Milder, similar to III-1 	—
III-8	67	5 th decade	<ul style="list-style-type: none"> • Gynecomastia, • DM, • back pain, • generalized weakness, • dysphagia, • dysphonia, • tremor, • atrophy, • areflexia, and • impotence 	<ul style="list-style-type: none"> • CPK ↑, • LDH ↔, • cholesterol ↑, • triglyceride ↑, and • CAG repeats on Xq in PCR ↑
III-10	63	4 th decade	<ul style="list-style-type: none"> • Gynecomastia, • generalized weakness, • dysphonia, and • fasciculation 	—
IV-17	20	—	<ul style="list-style-type: none"> • Gynecomastia (only) 	—

CPK = creatine phosphokinase; LDH = lactate dehydrogenase; EMG = electromyography; PCR = polymerase chain reaction; DM = diabetes mellitus; ↑ = increased; ↔ = normal; * The onset of gynecomastia was earlier.

presented in Table 1. A certain degree of genetic anticipation was observed. The disease had a variable age of onset and tempo of progression within a single generation. Hyperlipidemia was

more prominent than hyperglycemia. PCR was performed on 2 of the suspected carriers (cases V-2 and IV-13) and was positive in both.

Discussion

Like most other reported cases of the disease, our cases showed an X-linked recessive pattern of inheritance within the family. The clinical pattern of presentation and the laboratory findings (except for the prominence of hyperlipidemia) were also compatible with other reported cases. These findings show that this rather benign disease (compared to the more malignant and related disease, ALS) whose diagnosis is important from the standpoint of prognosis and genetic consultation can be easily diagnosed (at least clinically) considering the classical presenting features.

References

- 1 Victor M, Ropper AH. *Principles of Neurology*. 7th ed. New York: McGraw-Hill; 2001.
- 2 Bradley WG, Daroff RB, Fenichel GM, Marsden CD. *Neurology in Clinical Practice*. 3rd ed. Massachusetts: Butterworth-Heinemann; 2000.
- 3 La Spada AR, Fischbeck KH. Androgen-receptor gene defect in X-linked spinal and bulbar muscular atrophy. *Am J Hum Genet*. 1991; **49** (suppl): 20.
- 4 La Spada AR, Paulson HL, Fischbeck KH. Trinucleotide repeat expansion in neurological disease. *Ann Neurol*. 1994; **36**: 814 – 822.
- 5 Kennedy WR, Alter M, Sung JH. Progressive proximal spinal and bulbar muscular atrophy of late onset. A sex-linked recessive trait. *Neurology*. 1968; **18**: 671 – 680.
- 6 Kaimen-Maciel DR, Medeiros M, Climaco V, et al. X-linked recessive bulbospinal muscular atrophy (Kennedy's disease). A family study [in Portuguese]. *Arq Neuropsiquiatr*. 1998; **56**: 639 – 645.
- 7 Petrukhin AS, Zavadenko NN, Petrukhin AA, Evgrafov OV. The DNA diagnosis of a familial case of Kennedy's spinal and bulbar amyotrophy [in Russian]. *Zh Nevropatol Psikiatr Im S S Korsakova*. 1997; **97**: 45 – 48.
- 8 De Ferron E, Le Roux MG, Pascal O, Moisan JP, Feve JR. Molecular genetic study of a family with Kennedy syndrome including a symptomatic heterozygote [in French]. *Rev Neurol (Paris)*. 1994; **150**: 854 – 857.
- 9 Muradian GT, Tunian IuS, Khachunts AS, Samvelian KG. A familial case of Kennedy's X-linked bulbospinal amyotrophy [in Russian]. *Zh Nevropatol Psikiatr Im S S Korsakova*. 1993; **93**: 84 – 86.