

**European Society of Endocrinology clinical
practice guidelines on the management of
adrenal incidentalomas, in collaboration
with the European Network for the Study of
Adrenal Tumors**

▶ Adrenal incidentaloma: an adrenal mass detected on imaging not performed for a suspected adrenal disease. The imaging is not done for:

- ▶ Signs and symptoms potentially indicative of adrenal hormone excess
- ▶ Otherwise suspected adrenal disease
- ▶ Screening imaging in patients with a hereditary syndrome associated with an increased likelihood to develop adrenal tumors
- ▶ Tumor evaluation in extra- adrenal malignancies: However, as this is a clinically frequent scenario, we will address this in a specific section.

Table 2. Etiology of adrenal tumors presented as adrenal incidentaloma.^a

Etiology	Prevalence of the different entities among adrenal incidentalomas
Adrenocortical adenoma or macronodular bilateral adrenal hyperplasia	80%-85%
• Nonfunctioning	40%-70%
• Mild autonomous cortisol secretion	20%-50%
• Primary aldosteronism	2%-5%
• Overt Cushing's syndrome	1%-4%
Other benign mass	
• Myelolipoma	3%-6%
• Cyst and pseudocyst	1%
• Ganglioneuroma	1%
• Schwannoma	<1%
• Hemorrhage	<1%
Pheochromocytoma	1%-5%
Adrenocortical carcinoma	0.4%-4%
Other malignant mass (mostly adrenal metastases)	3%-7%

^aBased on references¹⁻¹⁴ Due to different selection criteria and the fact that different studies used different definitions of hormone excess, the range of the reported prevalence is particularly wide. Furthermore, these studies might be highly susceptible to selection, referral and reporting bias.

- ▶ **R.1.1. We recommend that patients with adrenal incidentalomas are discussed in a multidisciplinary expert team meeting, if at least one of the following criteria is met:**
 - ▶ Imaging is not consistent with a benign lesion.
 - ▶ There is evidence of hormone excess (including mild autonomous cortisol secretion [MACS] in patients with clinically relevant comorbidities potentially attributable to cortisol).
 - ▶ Adrenal surgery is considered.
 - ▶ Evidence of significant tumor growth during follow-up imaging.
- ▶ The core multidisciplinary team should consist of a radiologist, an endocrinologist, and a surgeon, all with significant experience in the management of adrenal tumors.

► **R.2.1 We recommend aiming to establish with the highest possible certainty if an adrenal mass is benign or malignant at the time of initial detection.**

- It is critical to know if an adrenal mass is malignant or benign as clinical management is dependent on establishing this fact, regardless of whether the mass is functioning or not.
- Malignant lesions may need urgent surgical intervention and other therapies, and delay may cause harm. Therefore, it is crucial that all images of patients with adrenal incidentaloma are reviewed by an experienced radiologist; also focusing on the contralateral adrenal, which is not rarely also hyperplastic or nodular.

- ▶ **R.2.2 We recommend that all adrenal incidentalomas undergo an imaging procedure to determine if the mass is homogeneous and lipid-rich and therefore benign ($\oplus\oplus\oplus\circ$). For this purpose, we recommend the use of noncontrast CT as the first imaging modality if not yet performed ($\oplus\oplus\oplus\circ$).**

- ▶ Change from guideline 2016: Increased level of incidence.

- ▶ 2016: We recommend that all adrenal incidentalomas undergo an imaging procedure to determine if the mass is homogeneous and lipid-rich and therefore benign ($\oplus\circ\circ\circ$). For this purpose, we primarily recommend the use of noncontrast CT ($\oplus\circ\circ\circ$).

Table 4. Imaging criteria to discriminate benign from malignant adrenal masses.^a

Method	Criteria favoring a benign mass	Strength of evidence ^b
Noncontrast CT	≤ 10 HU ^c	⊕⊕⊕○
FDG-PET/CT	Absence of FDG uptake or uptake less than the liver ^d	⊕○○○
MRI—chemical shift	Loss of signal intensity on out-phase imaging consistent with lipid-rich adenoma	⊕○○○
CT with delayed contrast media washout ^e	Relative washout $> 58\%$ ^f	⊕○○○

^aThese criteria apply only for masses with homogenous appearance, or masses that have other clear characteristics consistent with benign disease, eg, myelolipoma. A homogeneous mass is defined as a lesion with uniform density or signal intensity throughout. The measurements/region of interest (ROI) should include at least 75% of a lesion without contamination by tissues outside the adrenal lesion. Nonhomogeneous lesions should not be subjected to MRI or washout CT for further characterization.

^bThe strength of recommendation based on our systematic review on this topic (Section 4.1.1) and our personal experience.

^cThe majority of adrenal masses with HU 11-20 are also benign, especially in patients without history of extra-adrenal malignancy (see Section 4.1.1 and Reasoning R.2.4 for details).

^dCertain metastasis (eg, from kidney cancer or low grade lymphoma) may be FDG negative.

^eThere is no clear evidence about the best time interval. However, experienced adrenal radiologists prefer 15 min over 10 min.

^fThis cutoff based on a single study with only 253 adrenal tumors⁷² and has to be judged with caution and several older studies suggest a cutoff of 40%. Abbreviation: HU, Hounsfield unit.

- ▶ **R.2.3 We recommend that if the noncontrast CT is consistent with a benign adrenal mass (homogenous appearance and Hounsfield units [HU] ≤ 10), no further imaging is required ($\oplus\oplus\oplus\circ$).**

- ▶ Change from guideline 2016: Adapted criteria and increased the strength of recommendation and level of evidence.

- ▶ 2016: We suggest that if the noncontrast CT is consistent with a benign adrenal mass (HUs ≤ 10) that is homogeneous and smaller than 4 cm no further imaging is required ($\oplus\circ\circ\circ$).

- ▶ MRI with chemical shift should still be first choice only where a CT is less desirable (eg, pregnancy, children).
- ▶ If an MRI with chemical shift is already performed and the results are unambiguous, a multidisciplinary expert team might judge this as sufficient for an individual patient.

- ▶ **R.2.4 If CT demonstrates a homogeneous adrenal mass with unenhanced HU between 11 and 20 and a tumor size < 4 cm, and the results of the hormonal work-up do not indicate significant hormone excess, we suggest an immediate additional imaging to avoid any follow-up imaging ($\oplus\circ\circ\circ$). Alternatively, interval imaging in 12 months by noncontrast CT (or MRI) could be performed.**

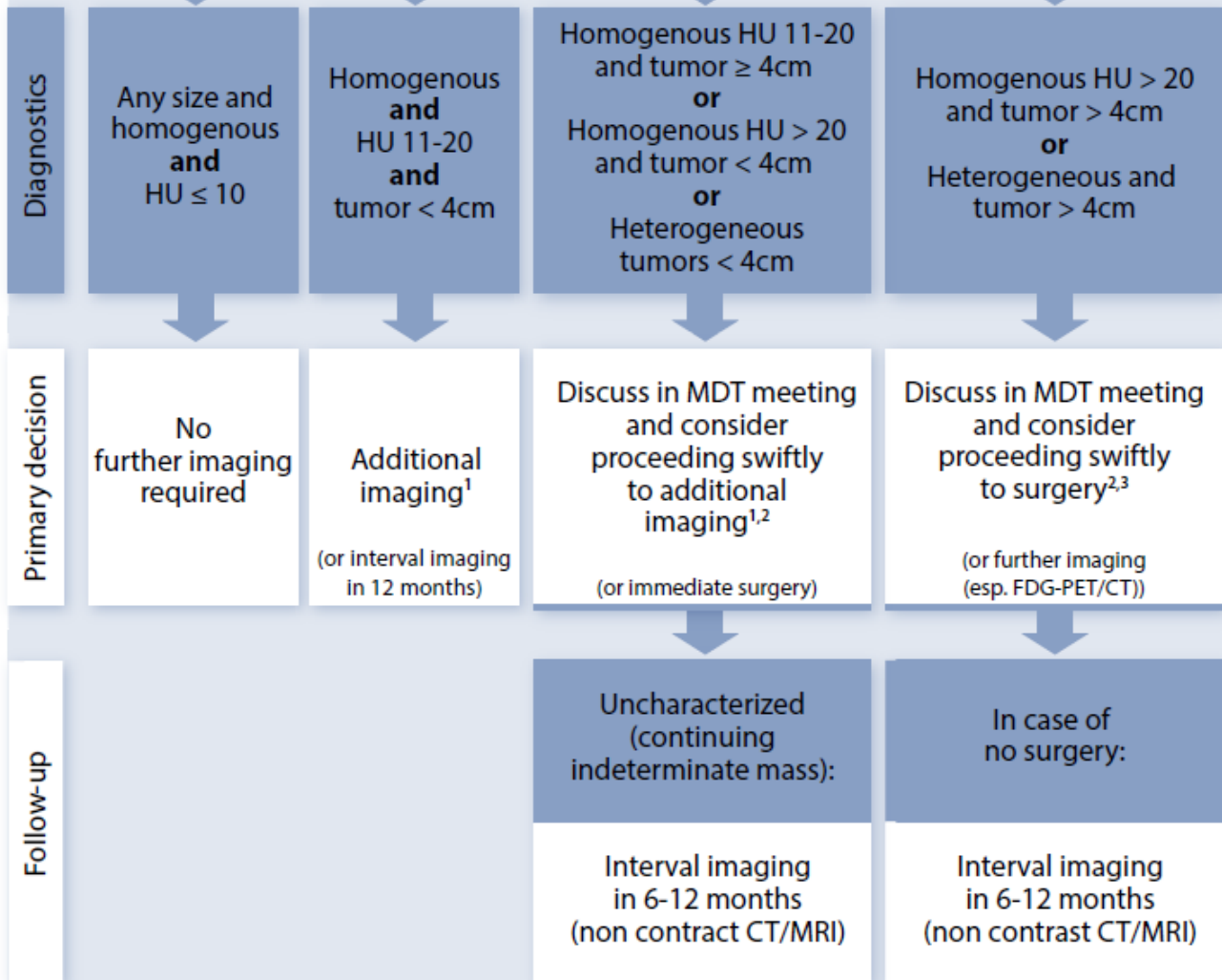
- ▶ **R.2.5 If the adrenal mass is ≥ 4 cm and heterogeneous or has unenhanced HU > 20 , there is a relevant risk that this lesion is malignant. Therefore, we suggest discussing such cases in a multidisciplinary team meeting. In most cases, immediate surgery will be the management of choice, but in some patients, additional imaging might be an option ($\oplus\circ\circ\circ$). Prior to surgery, we suggest completely staging the patient (including at least thoracic CT and/or FDG-PET/CT [$\oplus\circ\circ\circ$]). If surgery is not performed, follow up imaging in 6-12 months is recommended ($\oplus\circ\circ\circ$).**

- ▶ **R.2.6 In adrenal masses that do not fall in one of the categories above (eg, tumor size ≥ 4 cm with unenhanced HU 11-20; or tumor size < 4 cm with unenhanced HU > 20 ; or tumor size < 4 cm with heterogeneous appearance), we suggest an individualized approach with discussion in a multidisciplinary team meeting ($\oplus\circ\circ\circ$). The likelihood of a malignant tumor is still low. Therefore, in most cases, immediate additional imaging according to the center expertise and availability is the preferred option. If the tumor is still judged as indeterminate mass and surgery is not performed, we recommend interval imaging in 6-12 months (noncontrast CT/ MRI) ($\oplus\circ\circ\circ$).**

- ▶ Change from guideline 2016: Major modification.
- ▶ 2016: If the adrenal mass is indeterminate on noncontrast CT and the results of the hormonal work-up do not indicate significant hormone excess, 3 options should be considered by a multidisciplinary team acknowledging the patient's clinical context: immediate additional imaging with another modality, interval imaging in 6-12 months (noncontrast CT or MRI), or surgery without further delay.

Unenhanced CT

Imaging work-up in patients with adrenal incidentaloma



- ▶ A ***promising alternative***, where available, with high specificity for adrenocortical carcinoma is ***urine steroid metabolomics***, combining urine steroid profiling by tandem mass spectrometry with machine learning-based steroid data analysis :positive predictive value of 76.4% and a negative predictive value of 99.7%.
- ▶ In the case of ***second-line imaging or urine steroid metabolomics*** suggesting ***benign disease***, or for any other ***reason surgery was not performed***, follow-up ***imaging in 6-12 months*** depending on the individually perceived risk of malignancy is the preferred strategy (except for tumors <4 cm and HU 11-20 that do not need such interval imaging).
- ▶ Since there are very few adrenocortical carcinomas that grow very slowly, ***few panelists even preferred imaging both after 6 and 12 months***.
- ▶ There are no published or commonly agreed size or volume cutoffs that may be used that indicate growth suggestive of malignancy; the expert panel agreed in line with RECIST 1.1 criteria, an increase of >20% of the largest tumor diameter together with at least 5 mm increase in this diameter should be considered as suspicious.
- ▶ However, if there is no change in size, no further imaging is needed.

- ▶ **R.2.7 We recommend against the use of an adrenal biopsy in the diagnostic work-up of patients with adrenal masses unless there is a history of extra-adrenal malignancy (see R.6.3.5).**

- ▶ **R.2.8 We suggest measurement of sex steroids and precursors of steroidogenesis (ideally using multisteroid profiling by tandem mass spectrometry) in patients in whom by imaging or clinical features an adrenocortical carcinoma is suspected ($\oplus\oplus\circ\circ$).**

- ▶ Adrenocortical carcinoma is associated in more than half of cases with elevated sex hormones and/or steroid precursors.
- ▶ The panel does not recommend measurement of these hormones in patients with adrenal incidentalomas on a routine basis, but in cases with indeterminate adrenal mass by imaging or clinical signs for androgen or estrogen excess (eg, rapid virilization in women or rapidly developing gynecomastia in men), significantly increased sex hormones or precursors might clearly point toward adrenocortical carcinoma.
- ▶ Thus, measurement of serum DHEA-S, androstenedione, 17-hydroxyprogesterone, 11-deoxycortisol, as well as testosterone in women and estradiol in men and postmenopausal women can give clear indication of the adrenocortical nature of the adrenal mass. However, the panel acknowledges that the published evidence for this suggestion is very low.
- ▶ By combining the results of a machine learning algorithm processing urine steroid multi-profiling data with CT features (tumor size and HU on unenhanced CT), a prospective study on this topic with more than 2000 patients demonstrated that it is possible to reduce significantly the number of surgeries of indeterminate tumors wrongly suspected to be adrenocortical carcinoma. Therefore, the evidence is strongest for this method.
- ▶ However, urine steroid metabolomics is not yet widely available and is only validated and standardized in very few laboratories. Furthermore, it is not able to identify nonadrenocortical malignant adrenal masses.

- ▶ **R.3.1 We recommend that every patient with an adrenal incidentaloma should undergo careful assessment including clinical examination for symptoms and signs of adrenal hormone excess.**

► **R.3.2 We recommend that patients with adrenal incidentalomas undergo a 1-mg overnight dexamethasone suppression test to exclude autonomous cortisol secretion ($\oplus\oplus\oplus\circ$). In frail patients with limited life expectancy, this test may not be warranted.**

► Change from guideline 2016: Increased level of evidence and added a statement on frail patients.

► 2016: We recommend that all patients with adrenal incidentalomas undergo a 1-mg overnight dexamethasone suppression test to exclude cortisol excess ($\oplus\oplus\circ\circ$).

- ▶ **R.3.3 We recommend interpretation of the results of the 1-mg overnight dexamethasone test as a continuous rather than categorical (yes/no) variable ($\oplus\circ\circ\circ$). However, we recommend using serum cortisol levels post dexamethasone ≤ 50 nmol/L (≤ 1.8 $\mu\text{g/dL}$) as a diagnostic criterion for the exclusion of autonomous cortisol secretion ($\oplus\oplus\circ\circ$).**

- ▶ Change from guideline 2016: Increased the strength of recommendation.

- ▶ 2016: We suggest interpretation of the results of the 1-mg overnight dexamethasone test as a continuous rather than categorical (yes/no) variable ($\oplus\circ\circ\circ$). However, we recommend using serum cortisol levels post dexamethasone ≤ 50 nmol/L (≤ 1.8 $\mu\text{g/dL}$) as a diagnostic criterion for the exclusion of autonomous cortisol secretion ($\oplus\oplus\circ\circ$).

- ▶ **R.3.4 We recommend that in patients without signs and symptoms of overt Cushing's syndrome a post dexamethasone serum cortisol concentration above 50 nmol/L (> 1.8 µg/dL) should be considered as MACS without any further stratification based on the degree of cortisol nonsuppressibility ($\oplus\oplus\circ\circ$). In these patients, we recommend that ACTH-independency should be confirmed. Conditions that alter the results of the 1 mg DST should be considered for the interpretation of the results of the test. A repeat DST to confirm cortisol secretory autonomy is recommended. Additional biochemical tests to assess the degree of cortisol secretion might be useful. However, for clinical management the presence of comorbidities potentially attributable to cortisol excess, age, and the general condition of the patient are major factors for clinical decision-making.**

- ▶ Change from guideline 2016: Major modification.

- ▶ 2016: We suggest that post dexamethasone serum cortisol levels between 51 and 138 nmol/L (1.9-5.0 µg/dL) should be considered as evidence of "possible autonomous cortisol secretion" and cortisol levels post dexamethasone > 138 nmol/L (> 5.0 µg/dL) should be taken as evidence of "autonomous cortisol secretion." Additional biochemical tests to confirm cortisol secretory autonomy and assess the degree of cortisol secretion might be required. However, for the clinical management the presence of potentially cortisol-related comorbidities and age of the patient are of major importance.

- ▶ ***Some panelists*** felt that the measurement of ***serum DHEA-S*** or ***age- and sex- adjusted DHEAS ratios*** is helpful to identify patients with relevant MACS, ***especially in patients at risk of false positive*** of the 1 mg DST, because DHEA-S is decreased when the hypothalamus-pituitary-adrenal axis is chronically suppressed. However, age-adjusted DHEA-S reference values are not well established.

- ▶ The assessment of the presence of comorbidities potentially attributable to cortisol becomes of utmost importance to guide management. However, we are well aware that the likelihood of comorbidities increases with age. Furthermore, with increasing age cortisol after 1 mg DST is also increasing, and there is evidence that ***in patients >65 years the clinical relevance of MACS is decreasing***. Thus, this aspect has to be considered individually.
- ▶ In particular, in frail patients the documentation of MACS is very likely irrelevant and has no clinical consequences. Thus, ***the DST should be omitted in this patient group unless overt Cushing's syndrome is suspected***.
- ▶ Patients without detectable comorbidities should not undergo a specific treatment (ie, surgery) but require follow-up for the development of comorbidities potentially attributable to cortisol, while a subset of patients with relevant comorbidities should be considered for specific treatment.

- ▶ **R.3.5 We recommend against considering patients with MACS (per definition without specific clinical signs of Cushing's syndrome) as being at high risk for development of overt Cushing's syndrome ($\oplus\oplus\oplus\circ$).**

- ▶ Change from guideline 2016: Increased level of evidence.

- ▶ 2016: We recommend against considering “autonomous cortisol secretion” as a condition with a high risk for the development of overt Cushing's syndrome ($\oplus\oplus\circ\circ$).

- ▶ **R.3.6 We recommend screening patients with adrenal incidentaloma and MACS for hypertension and type 2 diabetes mellitus ($\oplus\oplus\circ\circ$) and suggest offering appropriate treatment of these conditions.**

- ▶ Change from guideline 2016: Increased level of evidence.

- ▶ 2016: We recommend screening patients with “possible autonomous cortisol secretion” or “autonomous cortisol secretion” for hypertension and type 2 diabetes mellitus ($\oplus\circ\circ\circ$) and suggest offering appropriate treatment of these conditions.

- ▶ **R.3.7 We suggest screening patients with adrenal incidentaloma and MACS for vertebral fractures ($\oplus\circ\circ\circ$) and to consider appropriate treatment of these conditions ($\oplus\circ\circ\circ$).**

- ▶ Some but not all studies found an increased incidence of asymptomatic vertebral fractures. However, accurate assessment of (micro-) fractures on X rays is not part of clinical practice everywhere. Therefore, at least overt fractures should be identified at the time of diagnosis. This can be done by ***asking patients about a history of nontraumatic fracture*** and, possibly, by ***reevaluating the available images*** (CT scan) or by ***plain X-ray***.
- ▶ Assessment of ***BMD by DXA***:
 - ▶ a ***suboptimal tool*** to diagnose glucocorticoid-induced osteoporosis
 - ▶ Furthermore, conflicting results on BMD in patients with MACS have been found. Few studies using noninvasive radiological evaluation of bone microarchitecture such as TBS found qualitative bone deterioration in MACS.
- ▶ However, the number of these studies is small requiring further confirmation and radiological evaluation of bone microarchitecture is not widely available. ***We therefore suggest to consider BMD*** especially in patients with MACS with clinical suspicion of osteoporosis or in the presence of associated risk factors for osteoporosis.

- ▶ **R.3.8 We recommend discussing the option of surgery with the patient who has MACS in addition to relevant comorbidities and a unilateral adrenal mass ($\oplus\circ\circ\circ$). Age, sex, general health, degree and persistence of nonsuppressible cortisol after dexamethasone, severity of comorbidities, and patient's preference should be taken into account ($\oplus\circ\circ\circ$). In all cases, the proposal to perform surgery should be established within an expert multidisciplinary group.**

- ▶ Change from guideline 2016: Major modification.

- ▶ 2016: We suggest an individualized approach to consider patients with “autonomous cortisol secretion” due to a benign adrenal adenoma and comorbidities potentially related to cortisol excess for adrenal surgery ($\oplus\circ\circ\circ$). Age, degree of cortisol excess, general health, comorbidities and patient's preference should be taken into account. In all patients considered for surgery, ACTH-independency of cortisol excess should be confirmed.


- ▶ Due to the limitations of current literature, especially the lack of high-quality randomized trials, ***the panel could not define the exact indications for surgery for patients with MACS.***
- ▶ The panel appreciated that there is some evidence of improvement of hypertension and hyperglycemia with surgery, but this is largely based on low quality data.
- ▶ However, there is no accurate assessment of the benefits of surgery. Furthermore, no data are available on more clinically relevant endpoints (eg, mortality or major cardiovascular events).
- ▶ Thus, the decision to undertake surgery should be individualized considering factors that are linked to outcome, such as patient's age, degree and persistence of cortisol autonomy on at least 2 separate evaluations, duration and evolution of comorbidities and their degree of control, and presence and extent of end organ damage.
- ▶ There was no complete agreement within the panel regarding the optimal management of these patients.

- ▶ Overall, the group agreed that there may be an indication for surgery in a patient with a unilateral adrenal mass, a post dexamethasone cortisol >50 nmol/L (>1.8 µg/dL) and the presence of at least one of the following features in the comorbidities potentially attributable to cortisol:
 - (1) progressive;
 - (2) difficult to treat;
 - (3) associated with inappropriate end organ damage for age;
 - (4) unusual for age or discrepant from family history; or
 - (5) multiple comorbidities.
- ▶ Given the lack of specific evidence, the panel felt that the presence of (some of) these features may suggest that normalization of cortisol autonomy has a greater likelihood to benefit patients who are operated on.
- ▶ Interestingly, there are 2 recent, large studies that suggest that mortality of patients with MACS is mainly increased in the cohort below the age of 65 years and in one of these studies particularly women younger than 65 years were affected. Thus, these patient group could potentially benefit most from a therapeutic intervention. However, data from intervention studies are not available yet.

▶ **R.3.9 We recommend excluding pheochromocytoma by measurement of plasma free metanephrines or urinary fractionated metanephrines in all patients with adrenal lesions with features not typical for a benign adenoma.**

▶ Change from guideline 2016: Restriction to a subset of patients.

▶ 2016: We recommend excluding pheochromocytoma by measurement of plasma free metanephrines or urinary fractionated metanephrines.

- 
- ▶ **R.3.10 In patients with concomitant hypertension or unexplained hypokalemia, we recommend use of the aldosterone/renin ratio to evaluate primary aldosteronism.**

- ▶ **R.4.1 We recommend adrenalectomy as the standard of care for unilateral adrenal tumors with clinically significant hormone excess. In patients with MACS, surgery can be considered in patients with relevant co-morbidities, taking into account individual factors (detailed in R.3.8).**

► **R.4.2 We recommend against performing surgery in patients with an asymptomatic, nonfunctioning unilateral adrenal mass and obvious benign features on imaging studies ($\oplus\oplus\circ\circ$).**

► Change from guideline 2016: Increased level of evidence.

► 2016: We recommend against performing surgery in patients with an asymptomatic, nonfunctioning unilateral adrenal mass and obvious benign features on imaging studies ($\oplus\circ\circ\circ$).

- ▶ **R.4.3 If surgery is indicated for a benign adrenal mass causing hormone excess (including MACS), we recommend that a minimally invasive approach is used (\oplus ○○○).**

- ▶ Change from guideline 2016: New recommendation.

- ▶ Benign adrenal masses causing MACS are usually <6 cm and can safely be removed by a minimally invasive surgical approach, which causes the least patient morbidity compared to an open approach.
- ▶ In the unusual circumstance where such an adrenal tumor is sufficiently large to cause concern about the possibility for removal by a minimally invasive approach, consultation by a very experienced center is advisable.

► **R.4.4 We suggest that minimally invasive adrenalectomy is performed by an expert high-volume adrenal surgeon in patients with unilateral adrenal masses with radiological findings suspicious of malignancy (R2.4-6) and a diameter ≤ 6 cm, but without evidence of local invasion ($\oplus\circ\circ\circ$).**

► Change from guideline 2016: Clarified language regarding minimally invasive adrenalectomy and added “expert high-volume adrenal surgeon.”

► 2016: We suggest performing laparoscopic adrenalectomy in patients with unilateral adrenal masses with radiological findings suspicious of malignancy and a diameter ≤ 6 cm, but without evidence of local invasion ($\oplus\circ\circ\circ$).

- ▶ **R.4.5 We recommend open adrenalectomy is performed by an expert high-volume adrenal surgeon for unilateral adrenal masses with radiological findings suspicious of malignancy and signs of local invasion ($\oplus\circ\circ\circ$).**

► **R.4.6 We recommend discussion of an individualized surgical approach by an expert high-volume adrenal surgeon in patients that do not fall in one of the above-mentioned categories in a multidisciplinary expert team meeting (\oplus ooo).**

► Change from guideline 2016: Increased the strength of recommendation and added “expert high-volume adrenal surgeon.”

► 2016: We suggest an individualized approach in patients that do not fall in one of the above-mentioned categories (\oplus ooo).

- ▶ the panel believes that a minimal annual workload of **12 adrenalectomies/year** seems to be **minimally required** to ensure sufficient experience in adrenal surgery, but **>20 adrenalectomies/year** are **desirable** for those involved in surgery for potentially malignant tumors.
- ▶ Furthermore, for suspected adrenocortical carcinoma specific expertise in oncological surgery is required.

- ▶ **R.4.7 We recommend perioperative glucocorticoid treatment at surgical stress doses in all patients undergoing surgery and a preoperative morning serum cortisol >50 nmol/L (1.8 µ/dL) after a 1 mg overnight dexamethasone test.**

- ▶ **R.4.8 We suggest that patients with MACS (similarly to patients with adrenal Cushing's syndrome) that underwent surgery should be followed by an endocrinologist until recovery of hypothalamic-pituitary-adrenal axis function has been documented.**

► **R.5.1 We recommend against further imaging during follow-up in patients with an adrenal lesion with clear benign features on imaging studies ($\oplus\oplus\oplus\circ$).**

- Change from guideline 2016: Increased the strength of recommendation and level of evidence; skipped size cutoff.
- 2016: We suggest against further imaging for follow-up in patients with an adrenal mass < 4 cm with clear benign features on imaging studies ($\oplus\circ\circ\circ$).

- ▶ **R.5.2 In patients with an indeterminate adrenal mass (by imaging), opting not to undergo adrenalectomy following initial assessment, we suggest one repeat noncontrast CT or MRI after 6-12 months to exclude significant growth ($\oplus\circ\circ\circ$). We suggest surgical resection if the lesion enlarges by more than 20% in maximum diameter (in addition to at least a 5 mm increase in maximum diameter) during this period. If there is growth of the lesion below this threshold, additional imaging again after 6-12 months might be considered.**

- ▶ **R.5.3 We recommend against repeated hormonal work- up in patients with hormonal work-up results within the reference range at initial evaluation unless new clinical signs of endocrine activity appear or there is worsening of comorbidities (eg, hypertension, type 2 diabetes) ($\oplus\oplus\circ\circ$).**


- ▶ Change from guideline 2016: Increased the strength of recommendation and level of evidence.

- ▶ 2016: We suggest against repeated hormonal work-up in patients with a normal hormonal work-up at initial evaluation unless new clinical signs of endocrine activity appear or there is worsening of comorbidities (eg, hypertension and type 2 diabetes) ($\oplus\circ\circ\circ$).

- ▶ **R.5.4 In patients with MACS, who do not undergo an adrenalectomy, we recommend only annual reassessment of comorbidities potentially attributable to cortisol ($\oplus\oplus\circ\circ$). For this purpose, we suggest that discharge from specialized endocrine follow-up be considered and that monitoring of comorbidities potentially attributable to cortisol could be undertaken by primary health care providers, if adequate surveillance for comorbidities is available in the community ($\oplus\circ\circ\circ$). If these comorbidities develop or worsen, referral to an endocrinologist is suggested to reassess the endocrine status and reconsider the potential benefit of intervention.**

- ▶ Change from guideline 2016: Major modifications.

- ▶ 2016: In patients with “autonomous cortisol secretion” without signs of overt Cushing’s syndrome, we suggest annual clinical reassessment for cortisol excess comorbidities potentially related to cortisol excess ($\oplus\circ\circ\circ$). Based on the outcome of this evaluation the potential benefit of surgery should be considered.



▶ For this annual evaluation the following measures seems reasonable:

- ▶ HbA1c
- ▶ blood pressure (ideally as ambulatory measurement)
- ▶ LDL and HDL cholesterol, triglycerides
- ▶ body weight

- ▶ **R.6.1.1 We recommend that for patients with bilateral or multiple adrenal masses each adrenal lesion is assessed individually at the time of initial detection according to the same imaging protocol as for unilateral adrenal masses to establish whether each nodule is benign or malignant.**

- ▶ **R.6.1.2 We recommend that all patients with bilateral adrenal incidentalomas should undergo clinical and hormonal assessment identical to that in patients with unilateral adrenal incidentaloma.**

► **R.6.1.3 We suggest approaching bilateral disease according to the following 4-option schema based on the results of the imaging and hormonal work-up:**

- (1) bilateral (macronodular) hyperplasia**
- (2) bilateral adrenal adenomas**
- (3) 2 morphologically similar, but nonadenoma-like adrenal masses, and**
- (4) 2 morphologically different adrenal masses.**

In patients who do not fall in one of these categories, an individualized management plan is needed.

- ▶ **R.6.1.4 For patients with bilateral hyperplasia without autonomous cortisol secretion, we suggest measuring 17-hydroxyprogesterone to exclude congenital adrenal hyperplasia (CAH) due to 21-hydroxylase deficiency.**

- ▶ **R.6.1.5 For patients with bilateral (macronodular) hyperplasia or bilateral adenomas, we recommend assessment of comorbidities that are potentially attributable to MACS.**
- ▶ **R.6.1.6 In patients with bilateral metastases, lymphoma, infiltrative inflammatory disease, and hemorrhages, we recommend assessment for adrenal insufficiency.**



► Change from guideline 2016: Major modifications and new recommendations.

► 2016: We recommend that all patients with bilateral adrenal incidentalomas should undergo clinical and hormonal assessment identical to that in patients with unilateral adrenal incidentaloma. The same applies for the assessment of comorbidities that might be related to autonomous cortisol secretion. In addition, 17-hydroxyprogesterone should be measured to exclude congenital adrenal hyperplasia, and testing for adrenal insufficiency should be considered, if suspected on clinical grounds or if imaging suggests bilateral infiltrative disease or hemorrhages.

- ▶ **R.6.1.7 In patients with bilateral hyperplasia or bilateral adenomas and MACS, we suggest individualization of specific treatment options based on age, sex, degree of cortisol autonomy, general condition, comorbidities, and patient preference.**

- ▶ Change from guideline 2016: Major modifications.

- ▶ 2016: We suggest that for patients with bilateral incidentaloma the same recommendations regarding the indication for surgery and follow-up are used as for patients with unilateral adrenal incidentalomas.

► **R.6.1.8. We suggest against bilateral adrenalectomy in patients without clinical signs of overt Cushing's syndrome.**

► Change from guideline 2016: Major modifications.

► 2016: We suggest that in patients with bilateral adrenal masses bilateral adrenalectomy is not performed for ACTH-independent "autonomous cortisol secretion" without clinical signs of overt Cushing's syndrome. In selected patients, a unilateral adrenalectomy of the dominant lesion might be considered using an individualized approach considering age, degree of cortisol excess, general condition, comorbidities and patient preference.

- ▶ **R.6.2.1 We recommend urgent assessment of an adrenal mass in pregnant women and individuals <40 years of age because of a higher likelihood of malignancy as well as and clinically significant hormone excess.**
- ▶ **R.6.2.2 We suggest the use of MRI rather than CT in children, adolescents, and pregnant women if dedicated adrenal imaging is required.**

- ▶ **R.6.2.3 We suggest surgical resection if an adrenal mass is indeterminate on imaging in children, adolescents, pregnant women, and adults < 40 years of age.**

- ▶ Change from guideline 2016: New recommendation.

- ▶ **R.6.2.4 We recommend that investigation and management of patients with poor general health and a high degree of frailty be kept in proportion to potential clinical gain.**

- ▶ In contrast to the typical patient with adrenal incidentaloma (usually > 50 years), we would consider 1 follow-up imaging after 12 months also for a presumably benign adrenal mass in very young patients.

- ▶ **R.6.3.1 We recommend measurement of plasma or urinary metanephrines to exclude pheochromocytoma in patients with extra-adrenal malignancy with an indeterminate mass, even if the adrenal mass is likely to be a metastasis. We suggest additional hormonal work-up based on an individualized approach.**

- ▶ **R.6.3.2 We recommend that in patients with a history of extra-adrenal malignancy, adrenal lesions characterized as benign by noncontrast CT require no further specific adrenal imaging follow-up.**

- ▶ **R.6.3.3 In patients with a history of extra-adrenal malignancy, strong FDG uptake in the adrenal gland(s) on PET-CT is suggestive of metastasis. In case of moderate or no FDG uptake, further work-up with at least unenhanced CT is recommended.**

- ▶ Although some studies indicate that few adrenal metastases may have $HU \leq 20$, the vast majority of adrenal masses with $HU \leq 20$ are benign and imaging that is being used for investigation and follow-up of the underlying malignancy is usually sufficient for these patients.
- ▶ As mentioned, FDG-PET/CT is—despite several limitations—currently probably the most reliable imaging method in the assessment of an adrenal mass that is indeterminate by unenhanced CT. Although there are few malignant lesions that are FDG-negative, especially renal cancer, FDG-uptake will be high in most adrenal metastases.
- ▶ However, clinicians have to be aware that also a subset of benign tumors (especially if they are endocrine active) are FDG-positive.
- ▶ If the FDG-PET/CT was performed with only a contrast-enhanced CT in venous phase, an unenhanced CT might be needed to determine if the lesion is benign or malignant.

- ▶ **R.6.3.4 For indeterminate lesions in patients with a history of extra-adrenal malignancy, in whom the clinical management will be altered by the demonstration that the adrenal lesion is malignant, we suggest performing either an FDG-PET/CT (if not done already), surgical resection, or a biopsy (see also R.6.3.5). In all other patients, we recommend imaging follow-up at the same interval as imaging for the primary malignancy.**

- ▶ Change from guideline 2016: Emphasized subgroup of patients in whom alteration of management might occur.
- ▶ 2016: For indeterminate lesions in patients with a history of extra-adrenal malignancy, we recommend imaging follow-up assessing the potential growth of the lesion at the same interval as imaging for the primary malignancy. Alternatively, FDG-PET/CT, surgical resection or a biopsy (see also R.6.3.5) can be considered.

► **R.6.3.5 We recommend that 3 key criteria be fulfilled before adrenal biopsy is considered:**

- (1) the lesion is hormonally inactive (in particular, a pheochromocytoma has been excluded),
- (2) the lesion has not been conclusively characterized as benign by imaging, and
- (3) clinical management of the patient would be altered by knowledge of the histology.

- ▶ Adrenal biopsy may present with a significant nondiagnostic rate and a potential for complications.
- ▶ In patients with no other obvious metastatic lesions and when surgical removal of the lesion is an option, FDG-PET/CT should be considered in order to exclude metastases outside the adrenal that were not visualized by CT or MRI.
- ▶ If a biopsy is necessary, this should be performed by a specialist interventional radiologist/physician. In uncertain cases, it is reasonable to discuss upfront with the pathologist how much material is needed to perform a complete diagnostic work-up (eg, in lymphoma or sarcoma). Reading of the biopsy should be done by an experienced pathologist.

- ▶ **R.6.3.6 We recommend assessment of residual adrenal function in patients with large bilateral metastases.**

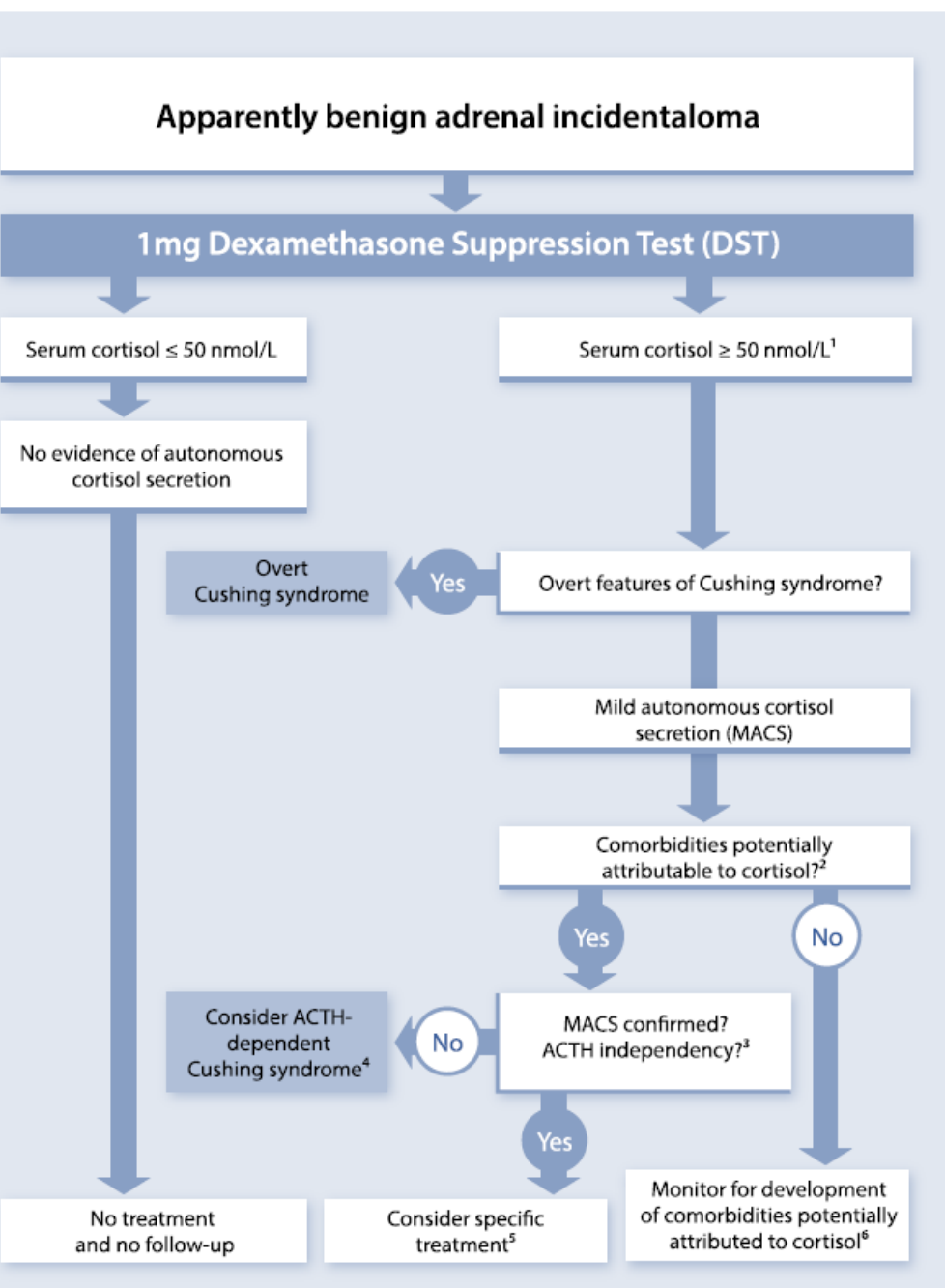


Figure 6. Assessment and management of mild autonomous cortisol secretion (MACS) in patients with adrenal incidentalomas. ¹Factors leading to false positive results have to be considered (see Table S16). Some panelists measure plasma ACTH already at this stage to prove ACTH-independency. ²The term comorbidities attributable to cortisol are defined broadly and includes diabetes mellitus, hypertension, dyslipidemia, or osteoporosis. ³Defined by low/suppressed morning plasma ACTH (and/or low age-adjusted DHEAS). ⁴An appropriate clinical context for triggering screening of ACTH-dependent Cushing is the presence of even mild stigmata of cortisol excess and/or clinically relevant comorbidities. ⁵Surgery is usually only indicated if comorbidities fulfill one or more of the following features: progressive; difficult to treat; associated with inappropriate end organ damage for age; unusual for age or discrepant from family history; or multiple comorbidities. In addition, age, sex, general health, degree, and persistence of nonsuppressible cortisol after dexamethasone, and patient's preference should be taken into account. ⁶Annual clinical reassessment of comorbidities potentially attributable to cortisol is recommended. If adequate surveillance for comorbidities is available in the community, this does not require a specialized endocrine follow-up. If these comorbidities develop or worsen, referral to an endocrinologist is suggested to reassess the endocrine status and reconsider the potential benefit of intervention.

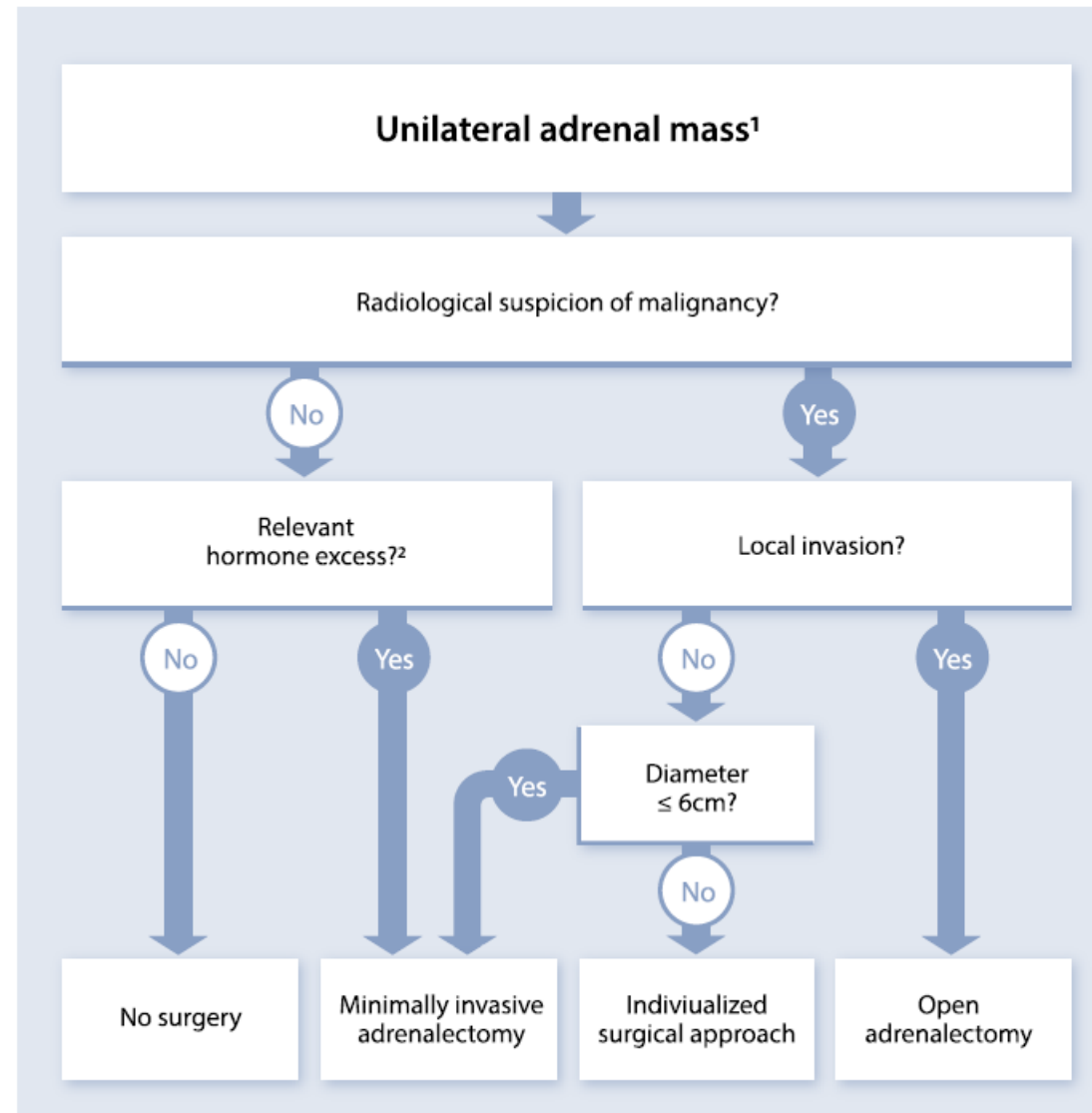


Figure 7. Flow-chart on the management of adrenal masses considered for surgery¹. ¹All patients considered for surgery should be discussed upfront in a multidisciplinary expert team meeting (see R1.1). ²In patients with MACS, an individualized decision-making process is required (see Section 5.3 for details).

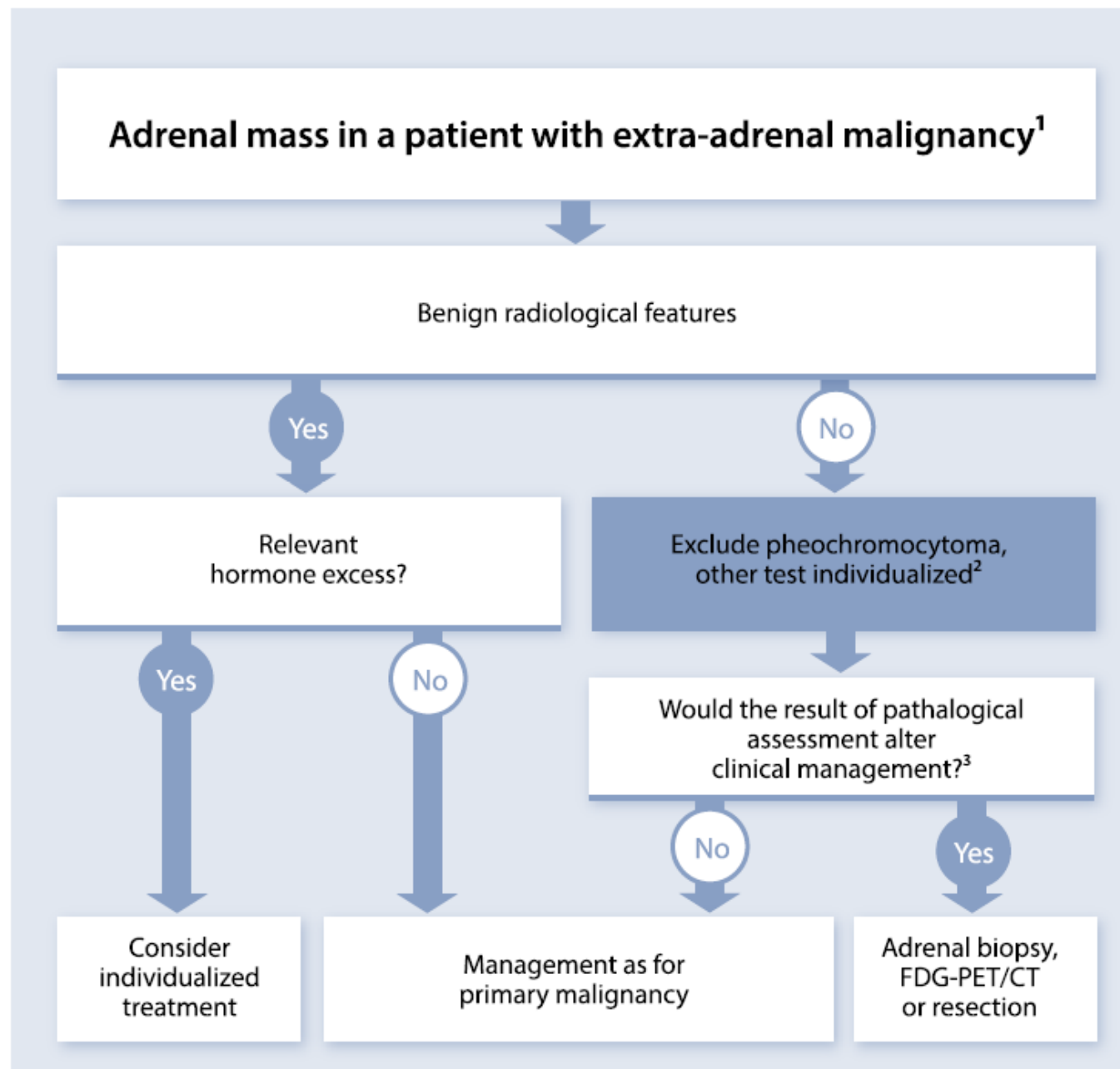


Figure 9. Evaluation of patients with adrenal mass and known extra-adrenal malignancy. ¹Always take life expectancy in consideration. ²If there is hormone excess, treat individualized. ³FDG-PET/CT should be considered to exclude other metastatic deposits in patients with no other obvious metastatic lesions for whom surgical removal of the lesion is an option.

