

## CLINICAL QUESTION

# Thyrotoxicosis associated with the use of amiodarone: the utility of ultrasound in patient management

Aikaterini Theodoraki and Mark P. J. Vanderpump

Department of Endocrinology, Royal Free London NHS Foundation Trust, London, UK

## Summary

Amiodarone is an anti-arrhythmic drug that commonly affects the thyroid, causing hypothyroidism or thyrotoxicosis. Amiodarone-induced thyrotoxicosis (AIT) is caused by excessive thyroid hormone biosynthesis in response to iodine load in autonomously functioning thyroid glands with pre-existing nodular goitre or underlying Graves' disease (type 1 or AIT 1), or by a destructive thyroiditis typically occurring in normal glands (type 2 or AIT 2). Indeterminate or mixed forms are also recognized. The distinction is clinically useful as AIT 1 is treated predominantly with thionamides, whereas AIT 2 is managed with glucocorticoids. We review the tools used to differentiate type 1 from type 2 thyrotoxicosis, with specific reference to the imaging modalities used.

(Received 30 October 2015; returned for revision 10 November 2015; finally revised 20 November 2015; accepted 23 November 2015)

## Introduction

Amiodarone is a very effective anti-arrhythmic drug, which causes thyroid dysfunction in about 15–28% of patients after 2–3 years of treatment.<sup>1,2</sup> It affects the thyroid gland and thyroid hormone metabolism by inherent effects of the drug, for example by inhibition of 5' monodeiodination, and by its high iodine content.<sup>3</sup> The underlying thyroid status and the environment, reflecting iodine intake, predispose patients to amiodarone-induced hypothyroidism (AIH) or amiodarone-induced thyrotoxicosis (AIT).

## Types of AIT

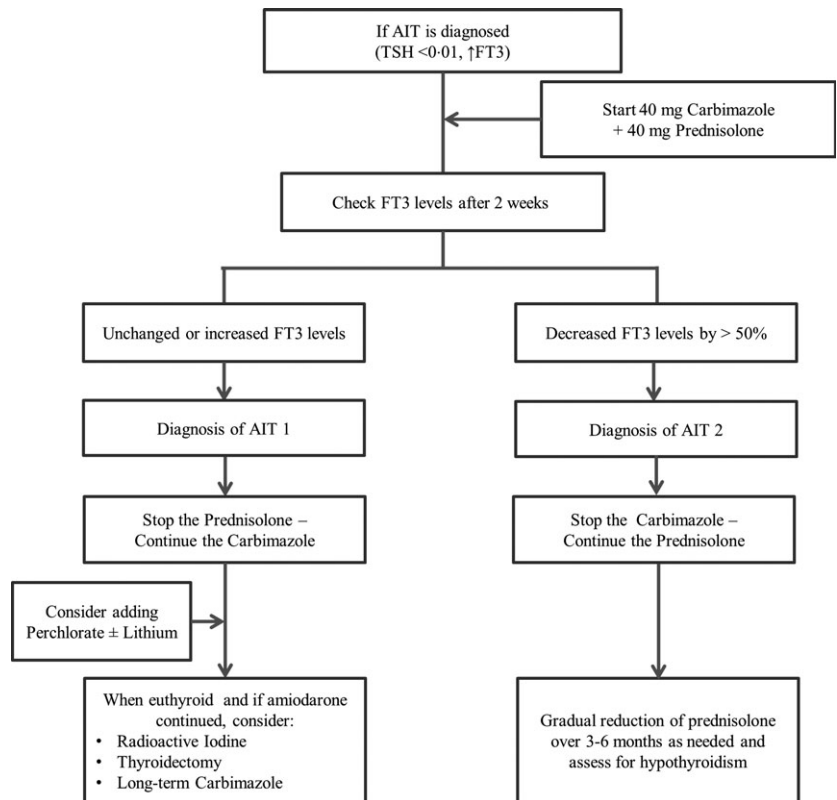
There are two mechanistically distinct types of AIT: AIT 1 and AIT 2. AIT 1 is a form of iodine-induced hyperthyroidism,

caused by excessive, uncontrolled biosynthesis of thyroid hormone by autonomously functioning thyroid tissue in response to iodine load, which typically develops in underlying nodular goitre or Graves' disease.<sup>2,4</sup> AIT 2 is a destructive thyroiditis occurring in an otherwise normal thyroid gland.<sup>5</sup> A mixed type is also recognized where patients acquire an overlapping condition of both types.<sup>6,7</sup> AIT 2 is more prevalent in iodine-sufficient areas.<sup>8,9</sup> Although spontaneous remission of AIT may occur whilst amiodarone is continued, there is significant associated mortality in this patient population with cardiovascular disease.<sup>10–12</sup> In this context, the management is challenging and the differentiation of AIT 1 from AIT 2 has therapeutic implications, as AIT 1 is managed with thionamides with the addition of potassium perchlorate in treatment-resistant patients, whereas AIT 2 is responsive to glucocorticoids.<sup>5,6,13</sup> The tools used to differentiate the two types of AIT are reviewed.

## Differentiation of AIT 1 and AIT 2: is it possible on clinical and biochemical grounds?

In its classic description, AIT 1 occurs in patients with pre-existing nodular or diffuse goitre, and AIT 2 in normal thyroid glands. However, the presence of a goitre or nodules is not specific for AIT 1.<sup>11,14</sup> In patients on amiodarone, serum-free thyroxine (FT<sub>4</sub>) typically lies between the upper end and up to 150% above the reference range; hence, it is a less useful test compared to free triiodothyronine (FT<sub>3</sub>) for the diagnosis of thyrotoxicosis.<sup>1</sup> The diagnosis of AIT therefore requires increased serum FT<sub>3</sub> and a suppressed serum TSH. The absolute levels of FT<sub>4</sub> and FT<sub>3</sub> at presentation have no discriminatory value between AIT 1 and AIT 2, although they tend to be higher in AIT 2<sup>12</sup> and they are helpful in diagnosing subclinical thyrotoxicosis. When patients with AIT 2 are given prednisolone, they achieve normal FT<sub>3</sub> after an average of 8 days, whereas patients with AIT 1 on methimazole require an average of 4 weeks to achieve a normal FT<sub>3</sub>.<sup>5</sup> The outcome of initial therapy may differentiate between AIT 1 and 2.<sup>5,6,11,13</sup> A proposed strategy is to use a treatment regimen of 40 mg carbimazole and 40 mg prednisone daily for 2 weeks: if FT<sub>3</sub> reduces by more than 50% compared with pretreatment levels, then a diagnosis of AIT 2 is most likely and thionamides can be discontinued (Fig. 1).<sup>13</sup>

Correspondence: Mark P. J. Vanderpump, Department of Endocrinology, Royal Free London NHS Foundation Trust, Pond Street, London, NW3 2QG, UK. Tel.: 0207 4726280; Fax: 0207 4726487; E-mail: mark.vanderpump@nhs.net



**Fig. 1** Proposed strategy for patients with AIT in whom the distinction between type 1 and type 2 is not possible (adapted from Han *et al.*<sup>1</sup>). Carbimazole (40 mg daily) therapy can be replaced by propylthiouracil (400 mg daily).

Antithyroid antibodies, such as thyroid peroxidase antibodies, are often positive in type 1 and negative in AIT 2.<sup>1</sup> Serum interleukin 6 (IL-6) was proposed as a marker of AIT 2, as levels are normal or slightly elevated in AIT 1 and markedly elevated in AIT 2.<sup>15,16</sup> However, in practice it has limited value<sup>12,14,17</sup> and the majority of thyroidologists in North America and Europe do not use it.<sup>18,19</sup>

### The role of imaging in the management of AIT

Nuclear medicine and ultrasound imaging have been utilized for differentiation of AIT 1, AIT 2 or mixed forms of the disease. The timing of imaging in the disease process matters.

### Nuclear medicine imaging

Three different tracers are available when assessing a hyperfunctioning thyroid anatomically: Radioiodine with <sup>131</sup>I or <sup>123</sup>I (RAI), Tc99m Pertechnetate (<sup>99m</sup>TcO<sub>4</sub><sup>-</sup>) and Tc99m SestaMIBI. The uptake of both RAI and <sup>99m</sup>TcO<sub>4</sub><sup>-</sup> at the molecular level is proportional to the expression of the thyroidal sodium/iodine symporter, and, outside the context of AIT, a strong and linear correlation between the <sup>99m</sup>TcO<sub>4</sub><sup>-</sup> uptake and RAI clearance is recognized.<sup>20,21</sup> SestaMIBI(MIBI) is a lipophilic monovalent cation with increased uptake in epithelial cells containing high numbers of mitochondria and is reduced or absent in apoptotic processes with mitochondrial membrane potential collapse.<sup>22</sup> MIBI retention occurs in hyperfunctioning thyroid tissue (toxic adenoma or toxic diffuse goitre).<sup>7</sup>

### RAI uptake in AIT

In areas of baseline low/borderline low iodine intake, AIT 1 is accompanied by low, normal or high 24-h RAI uptake (RAIU), whereas the RAIU is mostly zero in patients with AIT 2.<sup>23</sup> In iodine-replete environments, such as the United States, absent 24-h RAIU is invariably found in all patients taking amiodarone and it is not a useful investigation.<sup>14</sup> Even in environments with moderate iodine deficiency, such as Italy, RAIU has been shown to have low diagnostic value in differentiating AIT 1 from AIT 2. Some of the discrepancy in the results seems to arise from the presence of mixed forms of the disease. In a study by Bogazzi *et al.*, 3 patients with AIT 1 had low 3-h and 24-h RAIU values (presence of MN goitre in 2 and adenoma in 1), were unresponsive to methimazole and potassium perchlorate and became euthyroid after the addition of glucocorticoids. They were therefore likely to have a mixed form of AIT. Similarly, one patient with AIT 2 had inappropriately normal RAIU.<sup>24</sup> The data from studies comparing RAIU with other imaging modalities in this context are summarized in table 1.

### <sup>99m</sup>TcO<sub>4</sub><sup>-</sup> uptake in AIT

Outside the context of amiodarone treatment, <sup>99m</sup>TcO<sub>4</sub><sup>-</sup> scanning provides results highly comparable to RAIU. In all three studies where <sup>99m</sup>TcO<sub>4</sub><sup>-</sup> was used in patients with AIT, it showed mostly very low/no uptake in both AIT subtypes (Table 1).<sup>7,11,25</sup> The sensitivity for AIT 1 and specificity for AIT

**Table 1.** Summary of the evidence on the use of CFDS in the diagnosis of AIT type 1 or 2

Reference	Number of patients	CFDS (no. of patients)	RAIU Scan (no. of patients unless other specified)	$^{99}\text{TcO}_4^-$ Scan (no. of patients)	Final Diagnosis
Bogazzi <i>et al.</i> , 1997	27	AIT1: 11 AIT2: 16	AIT1: mean uptake 18%, range 6-51% AIT2: mean uptake 3%, range 0-6%	NA	AIT1: 11 AIT2: 16
Bogazzi <i>et al.</i> , 2003	55	AIT1: 16 AIT2: 39	AIT1: 13 AIT2: 41	NA	AIT1: 13 AIT2: 38 AIT Mixed: 4
Eaton <i>et al.</i> , 2002	25	AIT1: 10 AIT2: 10 AIT Mixed: 5	NA	NA	AIT1: 10 AIT2: 10 AIT Mixed: 5
Wong <i>et al.</i> , 2003	24	AIT1: 11 (mostly patterns I and II, one pattern III) AIT2: 13	NA	Very low/no uptake in 18/24- data per AIT type not available	AIT1: 11, but 4 CMZ only responsive, 1 steroid responsive ?how many mixed AIT2: 13, but 7/13 steroid responsiveness, ?5 mixed
Loy <i>et al.</i> , 2007	21	AIT1: 11 AIT2: 10	AIT1: 15, generally higher AIT2: 6, generally lower	AIT1: 9 true/2 false positives AIT2: 8 true/2 false positives	AIT1: 11 AIT2: 10
Piga <i>et al.</i> , 2008	20	AIT1: 9 AIT2: 10 AIT Mixed: 1	AIT1: 13 AIT2: 7	AIT1: 1 AIT2: 19	AIT1: 6 AIT2: 10 AIT Mixed: 4
Overall		Sensitivity	Specificity	References	
CFDS		AIT1: 96.8% AIT2: 93.6%	AIT1: 94.1% AIT2: 90.1%	7,11,12,15,24,25	
RAIU		AIT1: 90.9% AIT2: 84.7%	AIT1: 80.9% AIT2: 72.7%	7,24,25	
$^{99}\text{TcO}_4^-$		AIT1: 58.8% AIT2: 90.0%	AIT1: 91.7% AIT2: 47.6%	7,25	

The sensitivity and specificity of each method for different aetiologies was determined as before.<sup>30</sup>  
NA: not available.

2 from the available, albeit limited, data from only two studies are low.

#### Use of $^{99}\text{mTc}$ -sestaMIBI in AIT

A method that has shown promise in differentiating AIT 1 from AIT 2 or mixed cases is MIBI scanning.<sup>7</sup> In a prospective study, MIBI uptake was normal/increased in all six patients with AIT 1 and absent in all ten patients with AIT 2. In four patients with mixed forms of AIT, MIBI showed low, patchy and persistent uptake in two cases and in the other two evident MIBI uptake followed by a rapid washout. MIBI scintigraphy was able to completely differentiate AIT 1 from AIT 2 and was superior to other diagnostic tools.<sup>7</sup> MIBI scintigraphy was also superior to colour-flow Doppler sonography (which suggested AIT 2), in a report of a patient with mixed AIT.<sup>26</sup> Quantitative thyroid-to-background activity ratios on a time activity curve improve the agreement between MIBI reporters from 47% to 80% in the differentiation between type 1, 2 or

indeterminate AIT types, and therefore the diagnostic accuracy. However, the patient numbers studied so far are small ( $n = 15$ ).<sup>27</sup>

#### US Scanning in AIT

Sonography is easy and inexpensive for the rapid assessment of thyroid volume, nodularity, parenchymal echogenicity and vascularity.

#### Ultrasound scan by Grey Scale (GSS)

By definition, AIT 1 is associated with the presence of thyroid nodules or a diffuse goitre, although a goitre and nodules can also be present in AIT 2.<sup>7,11</sup> Thyroid volume was not different between the two AIT types in some studies<sup>11</sup> and was higher in AIT 1 in others.<sup>7,15,25</sup> Hypo-echoic glands can be found in both AIT 1 and AIT 2.<sup>15,25</sup> Overall, most evidence shows that standard thyroid sonography has low diagnostic value in AIT.<sup>25</sup>

### Colour-flow Doppler Sonography (CFDS)

CFDS provides a noninvasive, real-time assessment of thyroid vascularity. Blood flow changes in thyroid parenchyma or nodules, and systolic blood flow velocities of thyroid arteries can be estimated. In a hyperfunctioning thyroid gland, hypervascularity is observed, and CFDS has been used in the diagnosis of Graves' disease, solitary adenoma and toxic nodular goitre.<sup>28–30</sup> Peak systolic velocity of the superior thyroid artery has been shown to accurately differentiate Graves' disease from thyroiditis.<sup>31</sup> However, it has not been studied in AIT; hence, its usefulness in this context is speculative.

Bogazzi *et al.* first used CFDS to differentiate patients with AIT 1 from AIT 2.<sup>15</sup> The possible patterns were as follows: pattern 0 (absent intraparenchymal vascularity or minimal spots), pattern I (presence of parenchymal blood flow with patchy uneven distribution, or intranodular spots), pattern II (mild increase in Doppler signal with patchy distribution, or prominent flow at the periphery of the nodule) and pattern III (markedly increased Doppler signal with diffuse homogeneous distribution, or marked flow throughout the entire nodule). CFDS identified all 11 patients with AIT 1 who had increased vascularity of patchy distribution [with increasing vascularity: pattern I – 7 (64%); pattern II – 1 (9%); pattern III – 3 (27%)], whilst all 16 patients with AIT 2 showed absent vascularity (pattern 0). Normal controls and patients with subacute thyroiditis also had pattern 0 vascularity. These findings were confirmed in a subsequent cohort.<sup>24</sup>

A modification of this technique involves the separate assessment of parenchymal and nodular thyroid flow.<sup>25</sup> Qualitative CFDS patterns of the thyroid parenchyma (P) were classified as P1 (minimal parenchymal blood flow, as in a normal thyroid), P2 (mild increase in parenchymal flow with patchy distribution) and P3 (marked increase with diffuse homogeneous distribution). Thyroid nodules (N) were classified as N1 (absence of peri- and intranodular blood flow), N2 (perinodular and absent or slight intranodular flow), N3 (intranodular flow) and N0 (absence of nodules). P1N0 and P1N1 were defined as low/no blood flow patterns, and all others as increased flow patterns. Of the 11 patients with increased flow, 10 showed a hypervascular nodular pattern with absent parenchymal vascularization (P1N2 or P1N3) and one showed a hypervascular parenchymal pattern without detectable nodules (P3N0). Of the 10 patients with low/no flow, nine showed the P1N0 pattern (three with goitre) and one the P1N1 pattern (in the presence of a multinodular goitre). This classification is discrepant from the one used in a subsequent study.<sup>7</sup> The benefit of this classification is that it allows separate evaluation of parenchymal diseases. Outside the context of amiodarone treatment, CFDS was inconclusive in patients with parenchymal blood flow with uneven distribution, or in the presence of macronodules.<sup>30</sup>

On occasions, CFDS may show features that do not allow easy separation into different AIT groups, such as enlarged size with reduced vascularity or normal size with normal vascularity. A retrospective UK audit classified 20% of patients with AIT as having an indeterminate AIT type based on ultrasound appearances.<sup>12</sup>

An important clinical issue is the heterogeneity of treatment responses in a single CFDS pattern. In an Australian study, 13 of 24 patients showed a CFDS pattern of 0, consistent with AIT 2; however, only seven (58%) of these were prednisolone responsive. Of 11 patients with CFDS I–III, four (36%) responded to antithyroid medication alone and one of seven (14%) was prednisolone responsive.<sup>11</sup> Nevertheless, CFDS is useful in the management of AIT because CFDS 0 correlates better with prednisolone response than CFDS I–III, and it encourages a reduction or discontinuation of steroids in AIT 1.<sup>11,12</sup> The heterogeneity of responses to treatment may reflect the presence of mixed types of AIT, or a variable response of the same disease process to treatment.

In Table 1, the evidence on the use of CFDS in AIT compared with other imaging modalities is summarized. CFDS is the investigation of choice in AIT in Europe and North America.<sup>18,19</sup> However, the usefulness of CFDS depends on its availability and the necessary operator skills being available.

### Summary

Distinguishing between AIT 1, AIT 2 or mixed is important to guide the subsequent management. The recommended first-line treatment for AIT 1 is thionamides whilst glucocorticoids are usually required for AIT 2.<sup>6,17,18</sup> The diagnosis of AIT 2 is based on the absence of goitre, reduced RAIU in areas of iodine deficiency, absence of vascularity on CFDS and antithyroid antibody negativity. Often clinical decisions in the unwell patient and the outpatient setting need to be made before many or all of these investigations are available. A pragmatic approach has been suggested in which outcome of initial combined glucocorticoid and thionamide therapy may differentiate between type 1 and type 2 AIT (Fig. 1).<sup>5,6,11,13</sup> Although we have found this approach valuable in clinical practice, systematic review of patients treated with this algorithm would further clarify its usefulness. No imaging modality alone can accurately define the best treatment strategy which is at least partially due to the presence of mixed forms of the disease. Imaging may not always be necessary, such as in spontaneously remitting forms,<sup>12,14</sup> or when access to imaging is restricted and remission with treatment occurs. Overall, sound clinical judgement, taking into consideration the available results, is required in order to manage this group of patients safely.

### Conflict of interest

Nothing to declare.

### References

- Han, T.S., Williams, G.R. & Vanderpump, M.P. (2009) Benzofuran derivatives and the thyroid. *Clinical Endocrinology (Oxf)*, **70**, 2–13.
- Martino, E., Bartalena, L., Bogazzi, F. *et al.* (2001) The effects of amiodarone on the thyroid. *Endocrine Reviews*, **22**, 240–254.

- 3 Rao, R.H., McCready, V.R. & Spathis, G.S. (1986) Iodine kinetic studies during amiodarone treatment. *Journal of Clinical Endocrinology and Metabolism*, **62**, 563–568.
- 4 Harjai, K.J. & Licata, A.A. (1997) Effects of amiodarone on thyroid function. *Annals of Internal Medicine*, **126**, 63–73.
- 5 Bartalena, L., Brogioni, S., Grasso, L. *et al.* (1996) Treatment of amiodarone-induced thyrotoxicosis, a difficult challenge: results of a prospective study. *Journal of Clinical Endocrinology and Metabolism*, **81**, 2930–2933.
- 6 Bogazzi, F., Tomisti, L., Rossi, G. *et al.* Glucocorticoids are preferable to thionamides as first-line treatment for amiodarone-induced thyrotoxicosis due to destructive thyroiditis: a matched retrospective cohort study. *Journal of Clinical Endocrinology and Metabolism*, 2009, **94**, 3757–3762.
- 7 Piga, M., Cocco, M.C., Serra, A. *et al.* (2008) The usefulness of 99 mTc-sestaMIBI thyroid scan in the differential diagnosis and management of amiodarone-induced thyrotoxicosis. *European Journal of Endocrinology*, **159**, 423–429.
- 8 Sato, K., Miyakawa, M., Eto, M. *et al.*, *et al.* (1999) Clinical characteristics of amiodarone-induced thyrotoxicosis and hypothyroidism in Japan. *Endocrine Journal*, **46**, 443–451.
- 9 Bogazzi, F., Bartalena, L., Dell'Unto, E. *et al.* Proportion of type 1 and type 2 amiodarone-induced thyrotoxicosis has changed over a 27-year period in Italy. *Clinical Endocrinology (Oxf)*, 2007, **67**, 533–537.
- 10 O'Sullivan, A.J., Lewis, M. & Diamond, T. (2006) Amiodarone-induced thyrotoxicosis: left ventricular dysfunction is associated with increased mortality. *European Journal of Endocrinology*, **154**, 533–536.
- 11 Wong, R., Cheung, W., Stockigt, J.R. *et al.* (2003) Heterogeneity of amiodarone-induced thyrotoxicosis: evaluation of colour-flow Doppler sonography in predicting therapeutic response. *Internal Medicine Journal*, **33**, 420–426.
- 12 Eaton, S.E., Euinton, H.A., Newman, C.M. *et al.* (2002) Clinical experience of amiodarone-induced thyrotoxicosis over a 3-year period: role of colour-flow Doppler sonography. *Clinical Endocrinology (Oxf)*, **56**, 33–38.
- 13 Vanderpump, M.P. (2009) Thyroid gland: use of glucocorticoids in amiodarone-induced thyrotoxicosis. *Nature Reviews Endocrinology*, **5**, 650–651.
- 14 Daniels, G.H. (2001) Amiodarone-induced thyrotoxicosis. *Journal of Clinical Endocrinology and Metabolism*, **86**, 3–8.
- 15 Bogazzi, F., Bartalena, L., Brogioni, S. *et al.* (1997) Color flow Doppler sonography rapidly differentiates type I and type II amiodarone-induced thyrotoxicosis. *Thyroid*, **7**, 541–545.
- 16 Bartalena, L., Grasso, L., Brogioni, S. *et al.* (1994) Serum interleukin-6 in amiodarone-induced thyrotoxicosis. *Journal of Clinical Endocrinology and Metabolism*, **78**, 423–427.
- 17 Bogazzi, F., Bartalena, L. & Martino, E. (2010) Approach to the patient with amiodarone-induced thyrotoxicosis. *Journal of Clinical Endocrinology and Metabolism*, **95**, 2529–2535.
- 18 Tanda, M.L., Piantanida, E., Lai, A. *et al.* (2008) Diagnosis and management of amiodarone-induced thyrotoxicosis: similarities and differences between North American and European thyroidologists. *Clinical Endocrinology (Oxf)*, **69**, 812–818.
- 19 Bartalena, L., Wiersinga, W.M., Tanda, M.L. *et al.* (2004) Diagnosis and management of amiodarone-induced thyrotoxicosis in Europe: results of an international survey among members of the European Thyroid Association. *Clinical Endocrinology (Oxf)*, **61**, 494–502.
- 20 Meller, J. & Becker, W. (2002) The continuing importance of thyroid scintigraphy in the era of high-resolution ultrasound. *European Journal of Nuclear Medicine and Molecular Imaging*, **29** (Suppl 2), S425–S438.
- 21 Kusic, Z., Becker, D.V., Saenger, E.L. *et al.* (1990) Comparison of technetium-99m and iodine-123 imaging of thyroid nodules: correlation with pathologic findings. *Journal of Nuclear Medicine*, **31**, 393–399.
- 22 Chiu, M.L., Kronauge, J.F. & Piwnicka-Worms, D. (1990) Effect of mitochondrial and plasma membrane potentials on accumulation of hexakis (2-methoxyisobutylisonitrile) technetium(I) in cultured mouse fibroblasts. *Journal of Nuclear Medicine*, **31**, 1646–1653.
- 23 Martino, E., Bartalena, L., Mariotti, S. *et al.* (1988) Radioactive iodine thyroid uptake in patients with amiodarone-iodine-induced thyroid dysfunction. *Acta endocrinologica*, **119**, 167–173.
- 24 Bogazzi, F., Martino, E., Dell'Unto, E. *et al.* Thyroid color flow doppler sonography and radioiodine uptake in 55 consecutive patients with amiodarone-induced thyrotoxicosis. *Journal of Endocrinological Investigation*, 2003, **26**, 635–640.
- 25 Loy, M., Perra, E., Melis, A. *et al.* Color-flow Doppler sonography in the differential diagnosis and management of amiodarone-induced thyrotoxicosis. *Acta Radiologica (Stockholm, Sweden: 1987)*, 2007, **48**, 628–634.
- 26 Souto, S.B., Fernandes, H., Matos, M.J. *et al.* (2011) Importance of (99m)Tc-sestaMIBI thyroid scan in a case of amiodarone-induced thyrotoxicosis. *Arquivos brasileiros de endocrinologia e metabologia*, **55**, 486–489.
- 27 Pattison, D.A., Westcott, J., Lichtenstein, M. *et al.* (2015) Quantitative assessment of thyroid-to-background ratio improves the interobserver reliability of technetium-99m sestamibi thyroid scintigraphy for investigation of amiodarone-induced thyrotoxicosis. *Nuclear Medicine Communications*, **36**, 356–362.
- 28 Fobbe, F., Finke, R., Reichenstein, E. *et al.* (1989) Appearance of thyroid diseases using colour-coded duplex sonography. *European Journal of Radiology*, **9**, 29–31.
- 29 Boi, F., Loy, M., Piga, M. *et al.* (2000) The usefulness of conventional and echo colour Doppler sonography in the differential diagnosis of toxic multinodular goitres. *European Journal of Endocrinology*, **143**, 339–346.
- 30 Rosario, P.W., Santos, J.B., Nunes, N.S. *et al.* (2014) Color flow Doppler sonography for the etiologic diagnosis of thyrotoxicosis. *Hormone and Metabolic Research*, **46**, 505–509.
- 31 Zhao, X., Chen, L., Li, L. *et al.* (2012) Peak systolic velocity of superior thyroid artery for the differential diagnosis of thyrotoxicosis. *PLoS ONE*, **7**, e50051.